

## Key Opinion Leader Forum 4: PAD Acute Limb Ischaemia

**Maria Antonella Ruffino, MD, EBIR, FCIRSE**

Interventional Radiology Department

Imaging Institute of Southern Switzerland

Centro Vascolare Ticino

EOC – Ente Ospedaliero Cantonale

Lugano, Switzerland



## CASE 4

Male, 87 y.o

2015: prostatic cancer GS 3+4 – RT

Right hemiparesis (cervical myelopathy,  
spondyloarthritis)

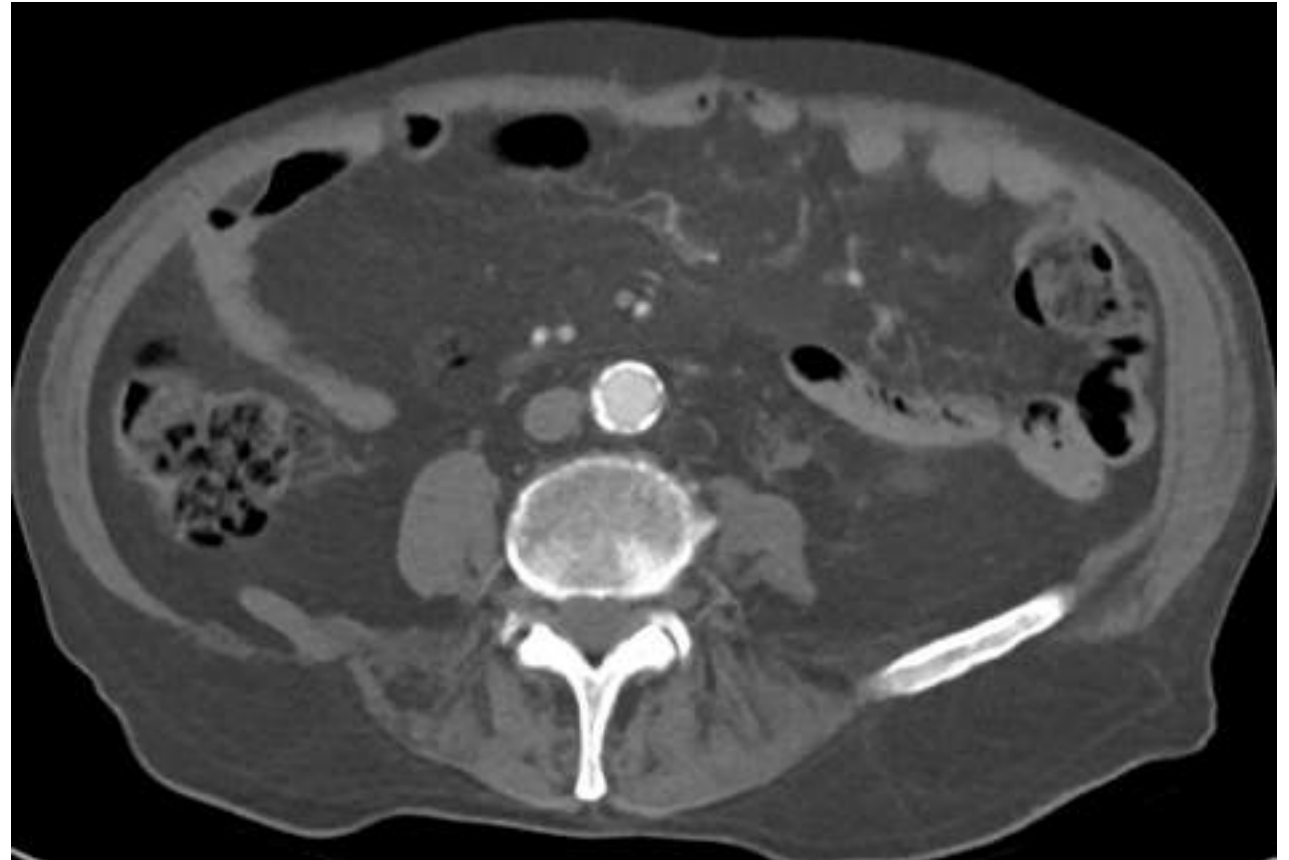
2009: Colon ca. pT3pN0 G2  
Left hemicolectomy

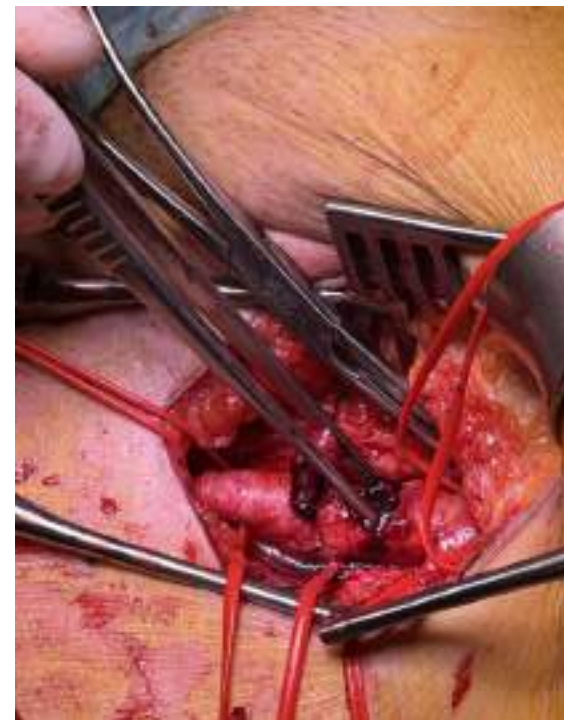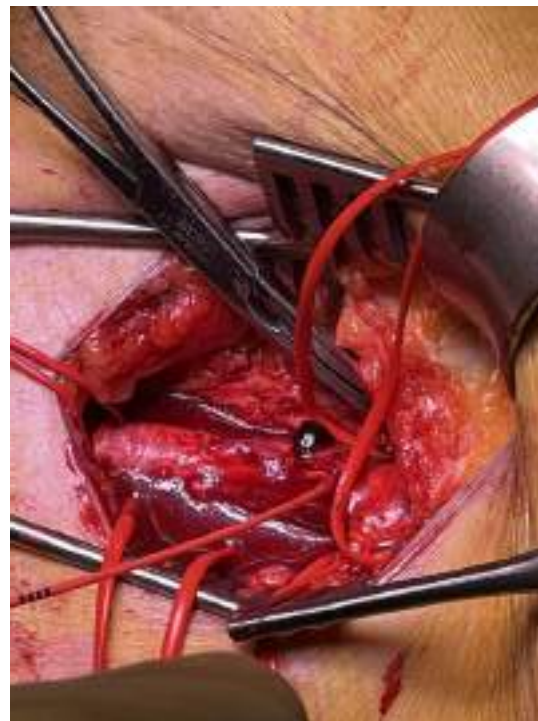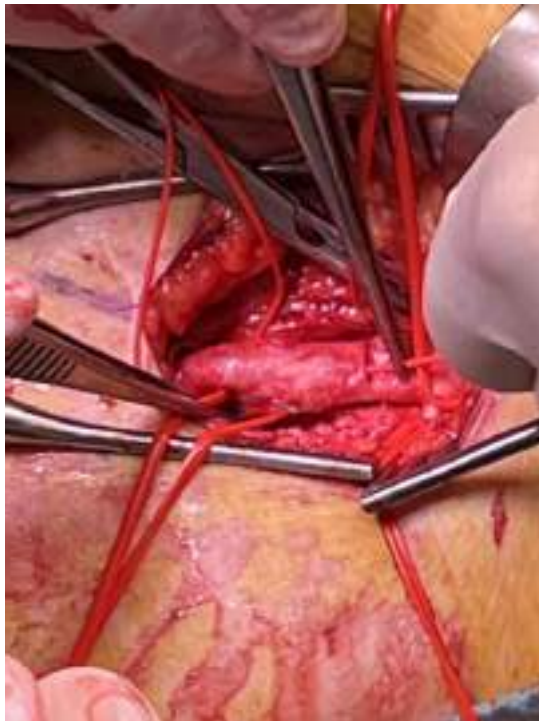

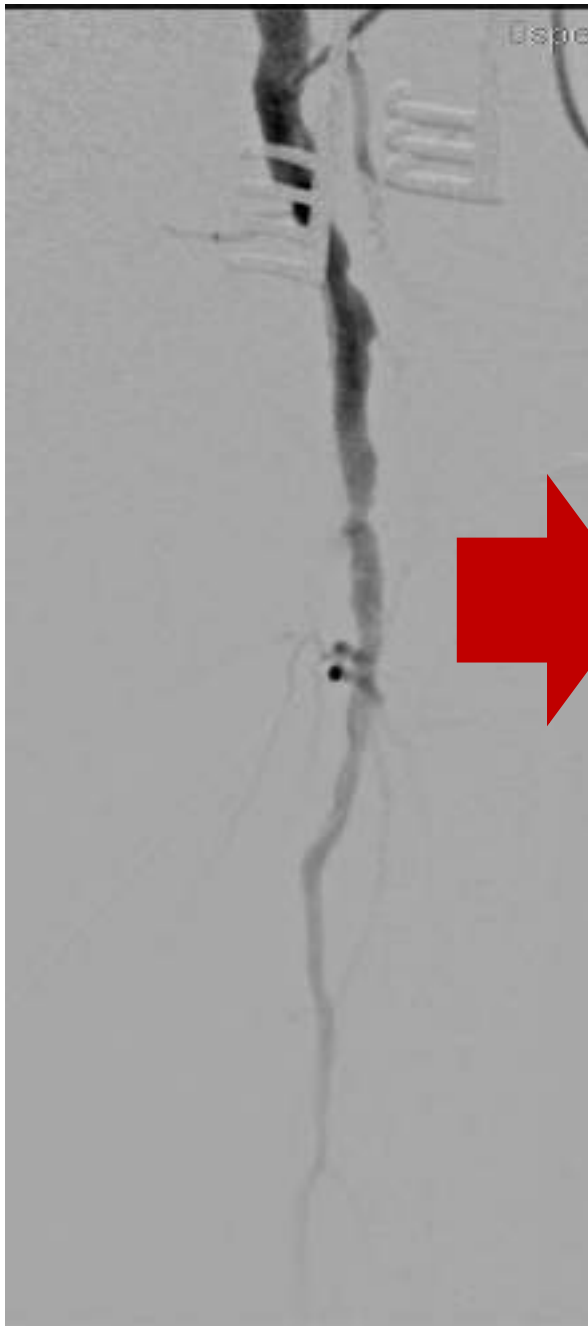
Thrombocytopenia: 30g/L

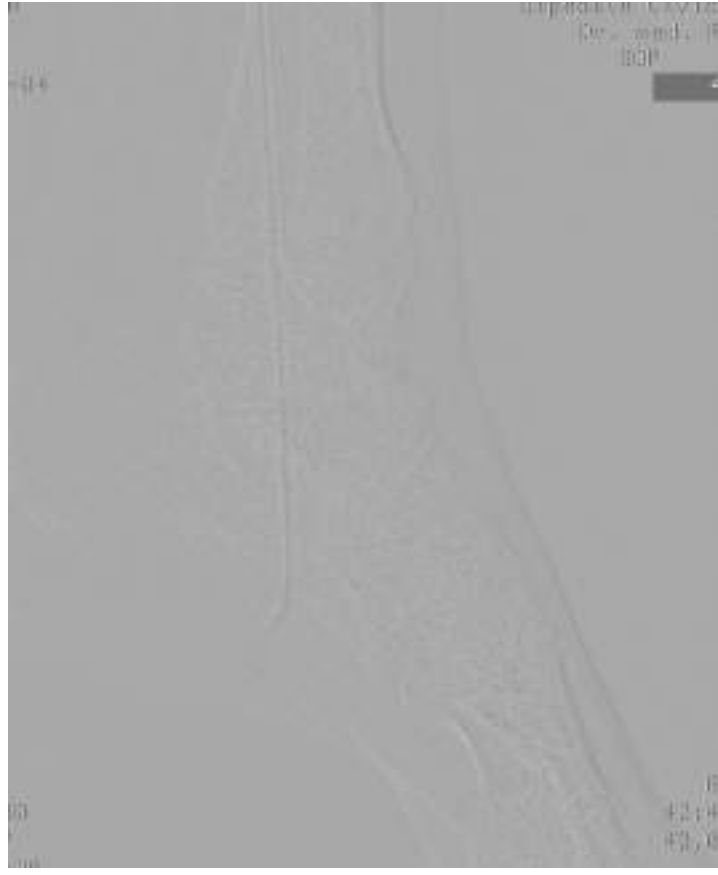
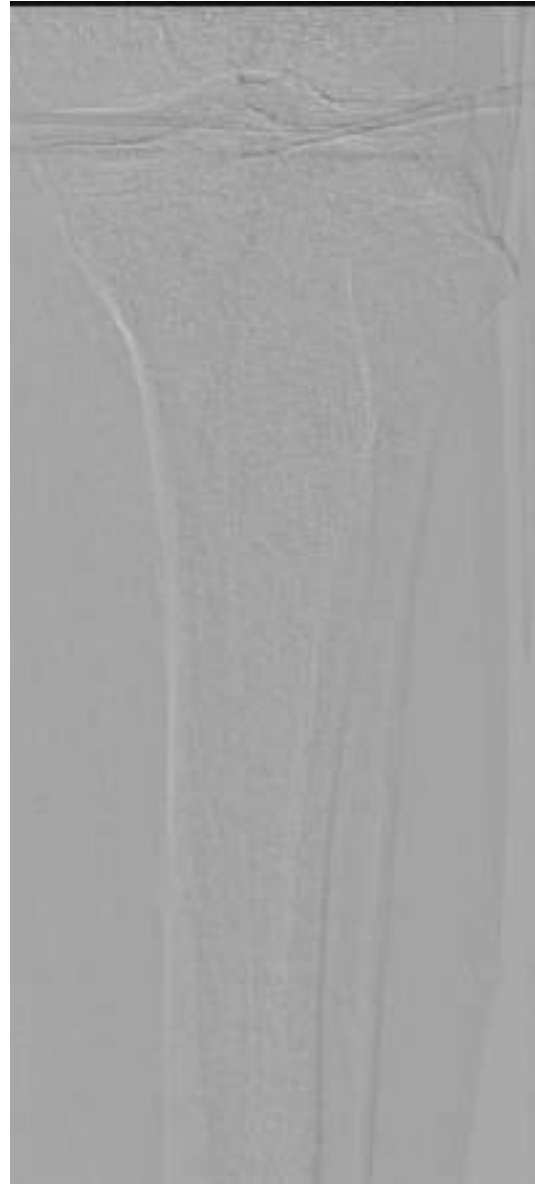
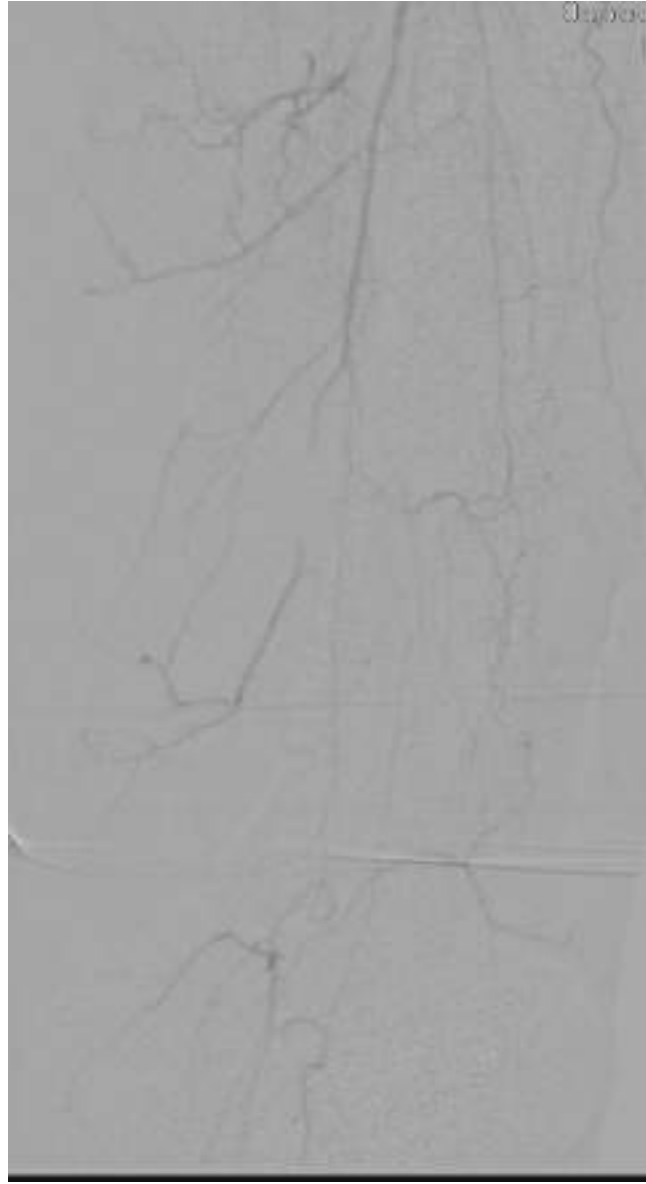
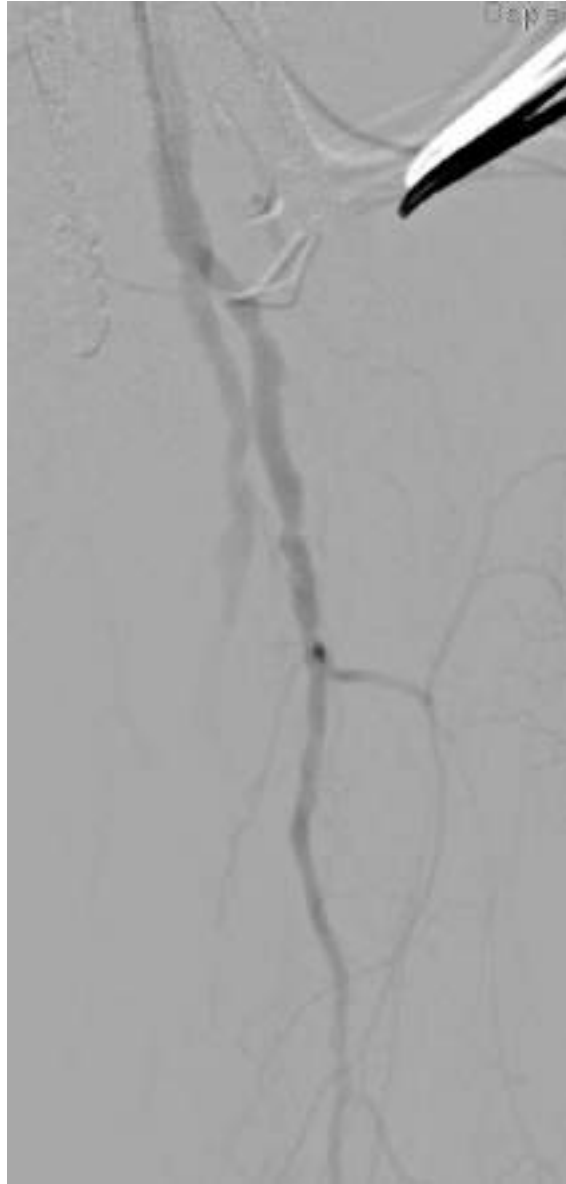
Acute onset of left lower limb pain  
No pulses on the left  
No sensitivity neither motility

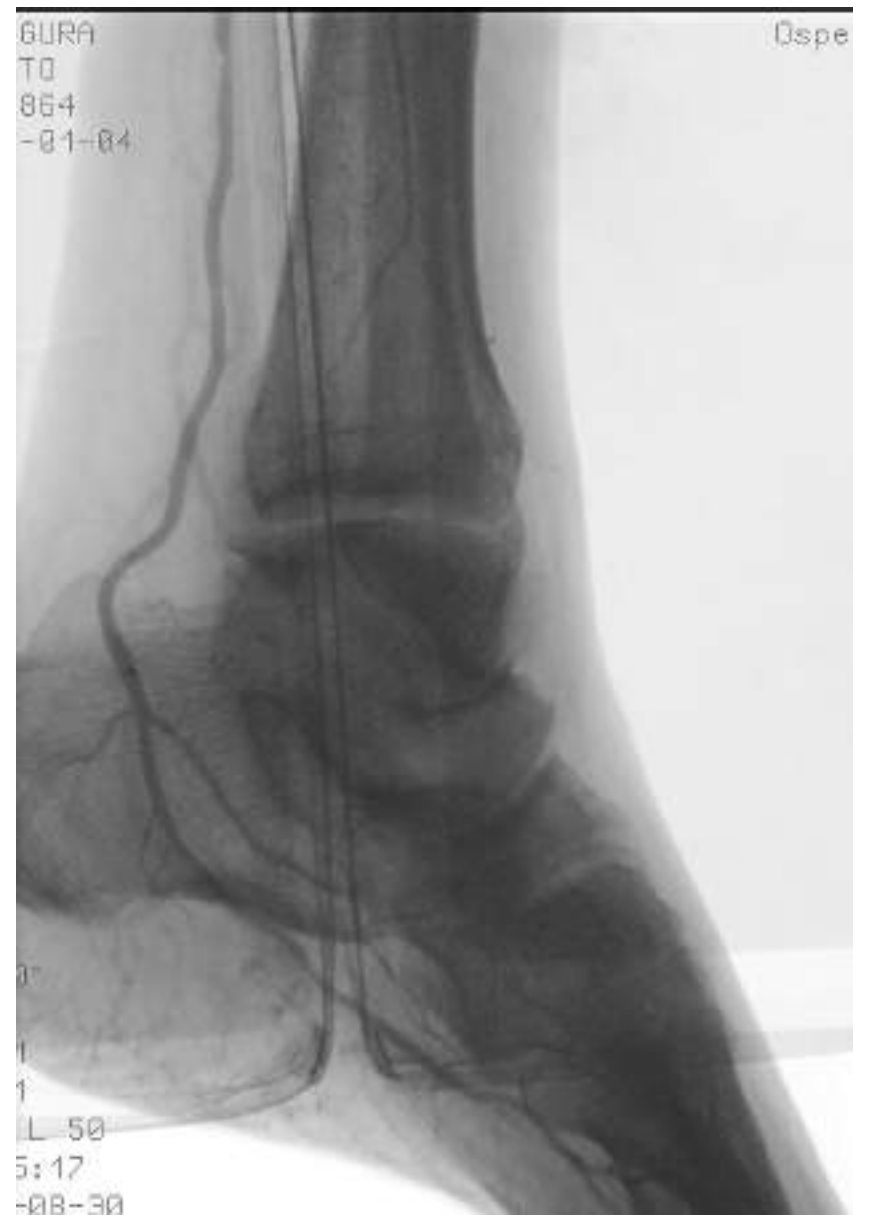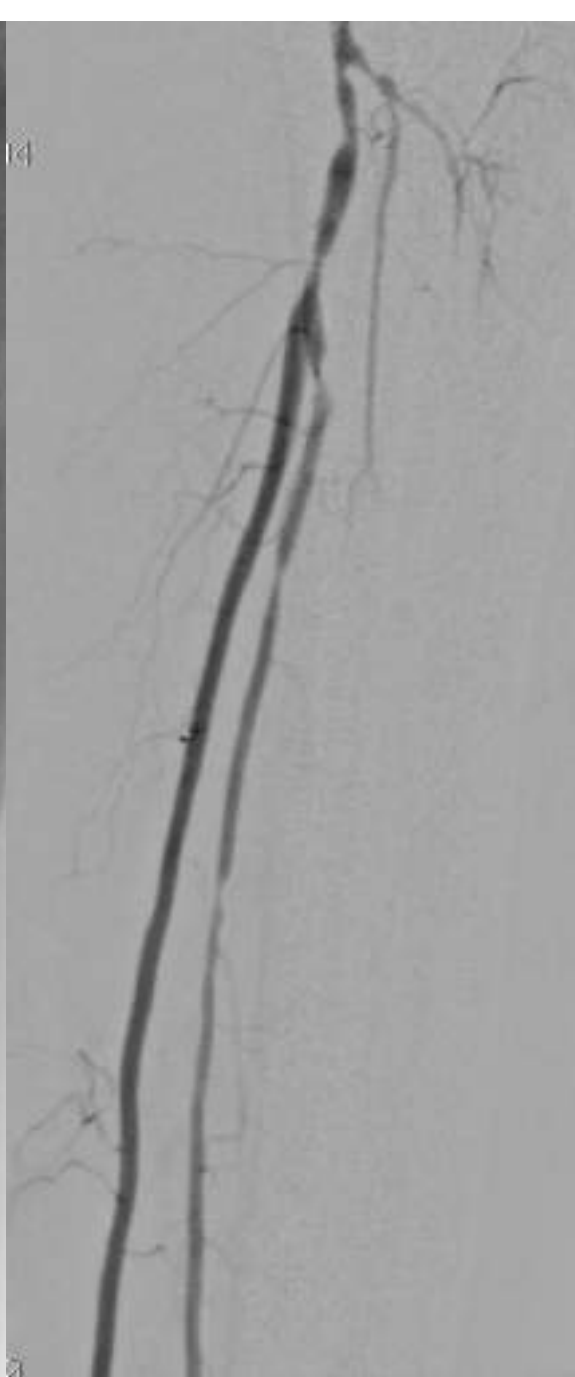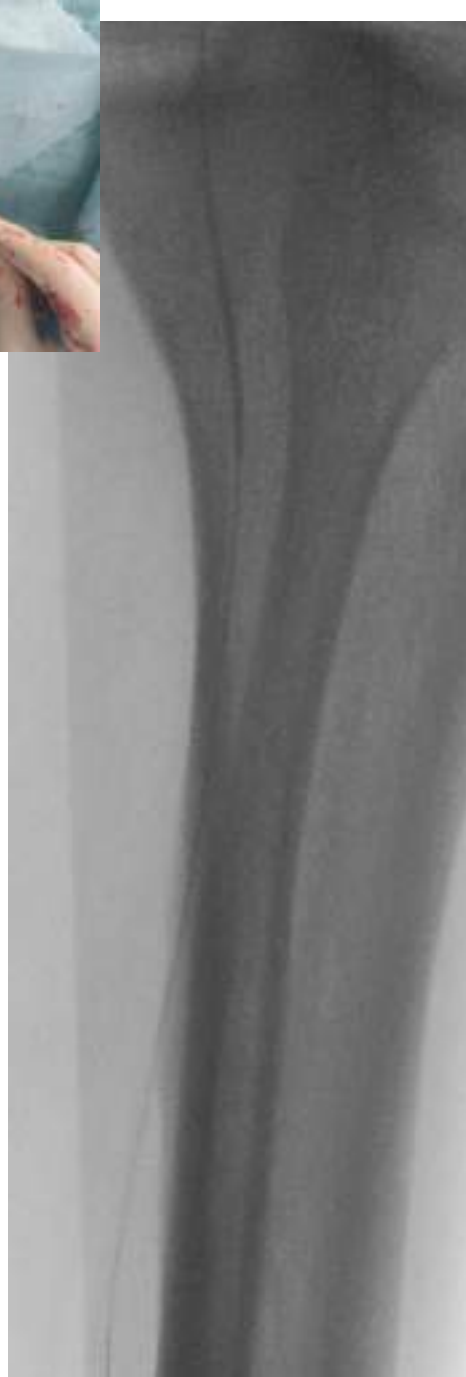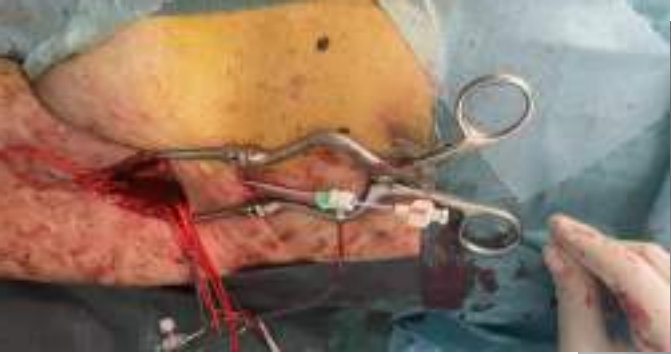### THERAPY:

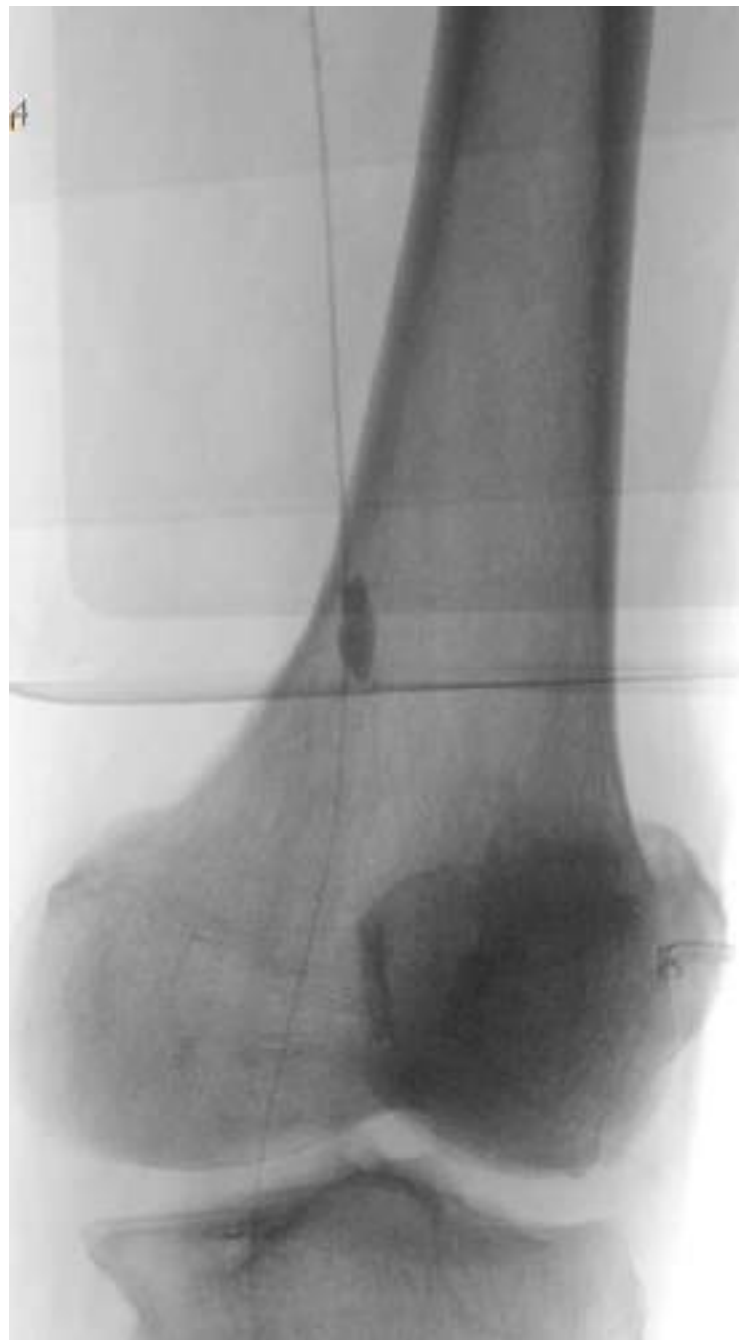
Prednison 75 mg/die

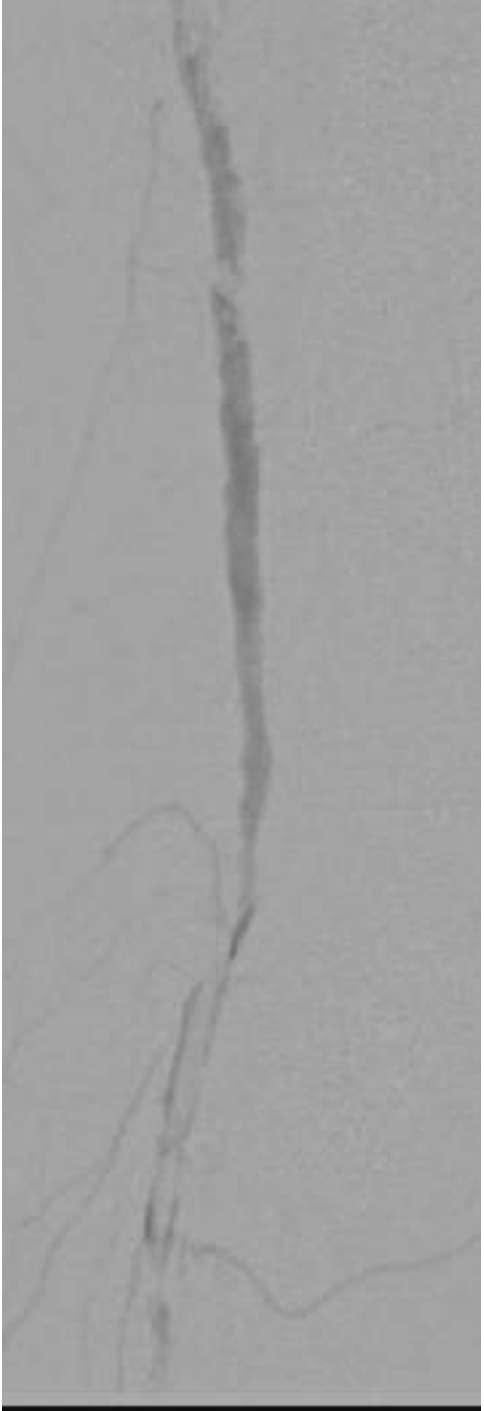
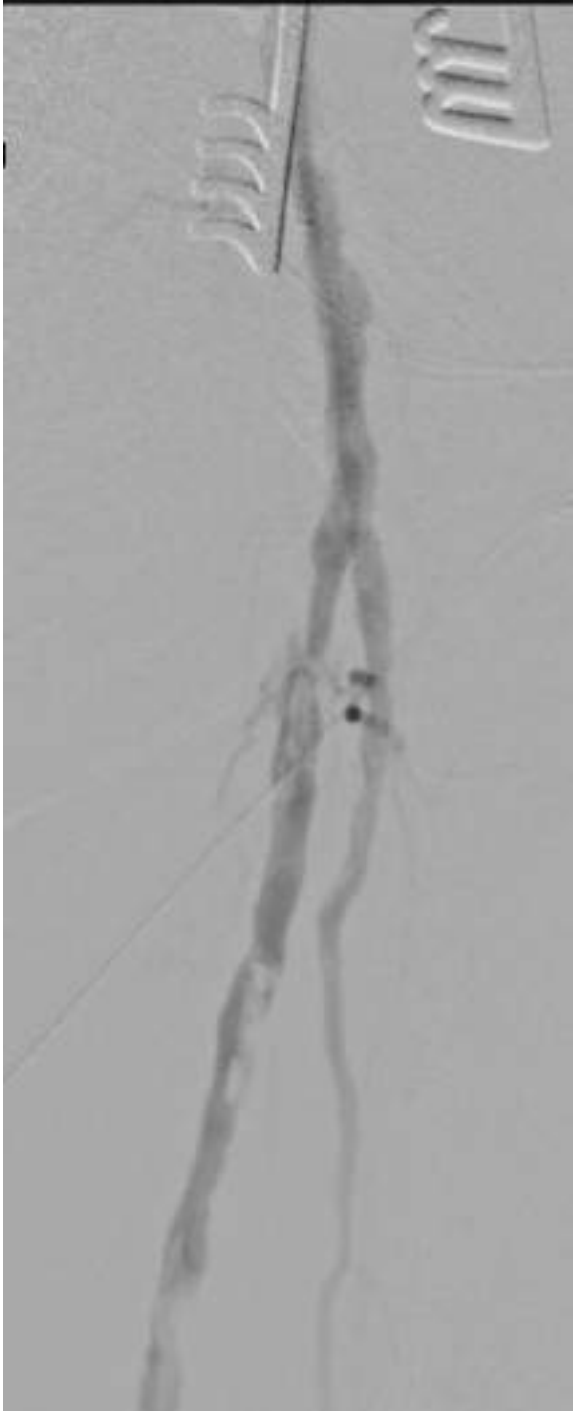


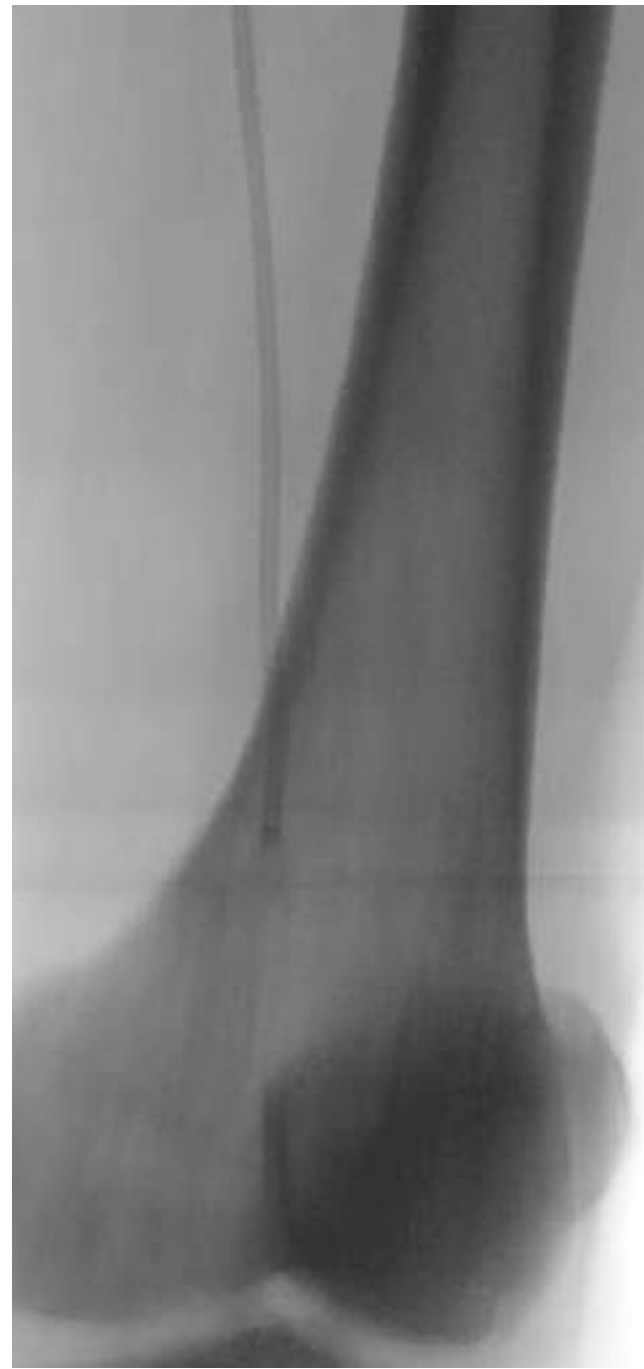

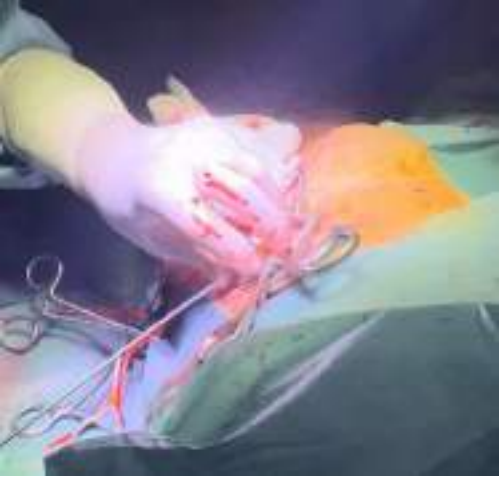

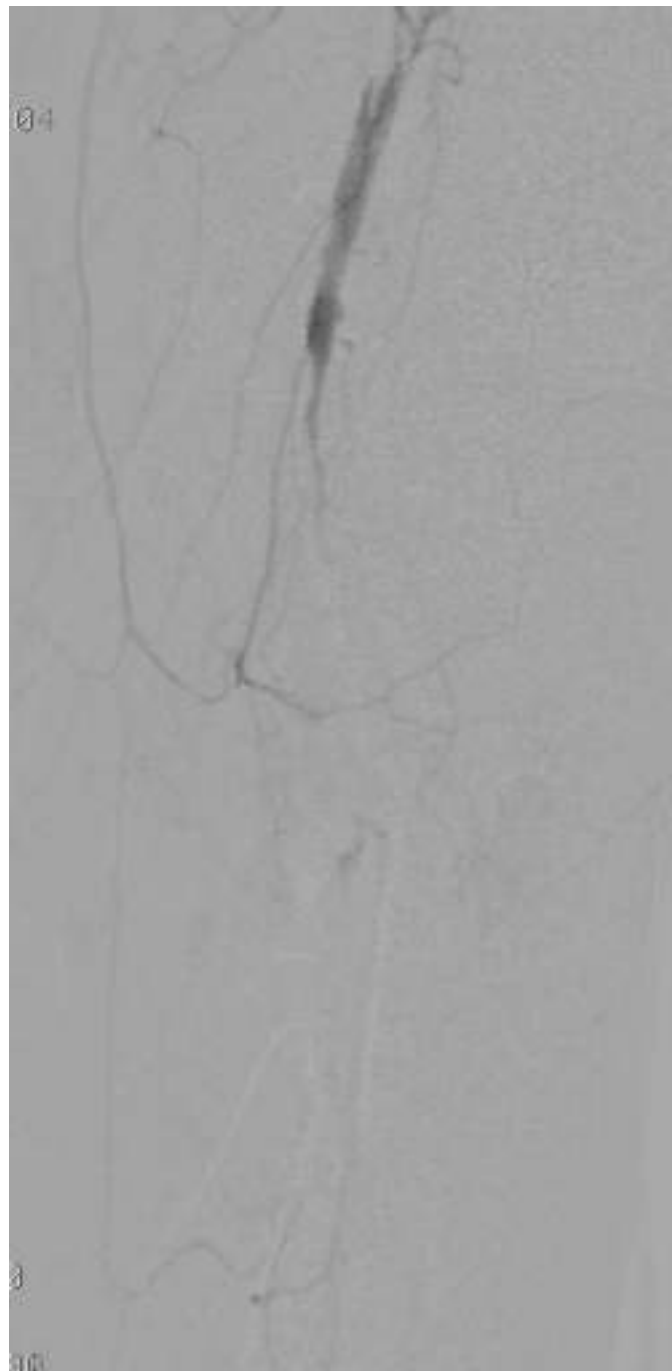
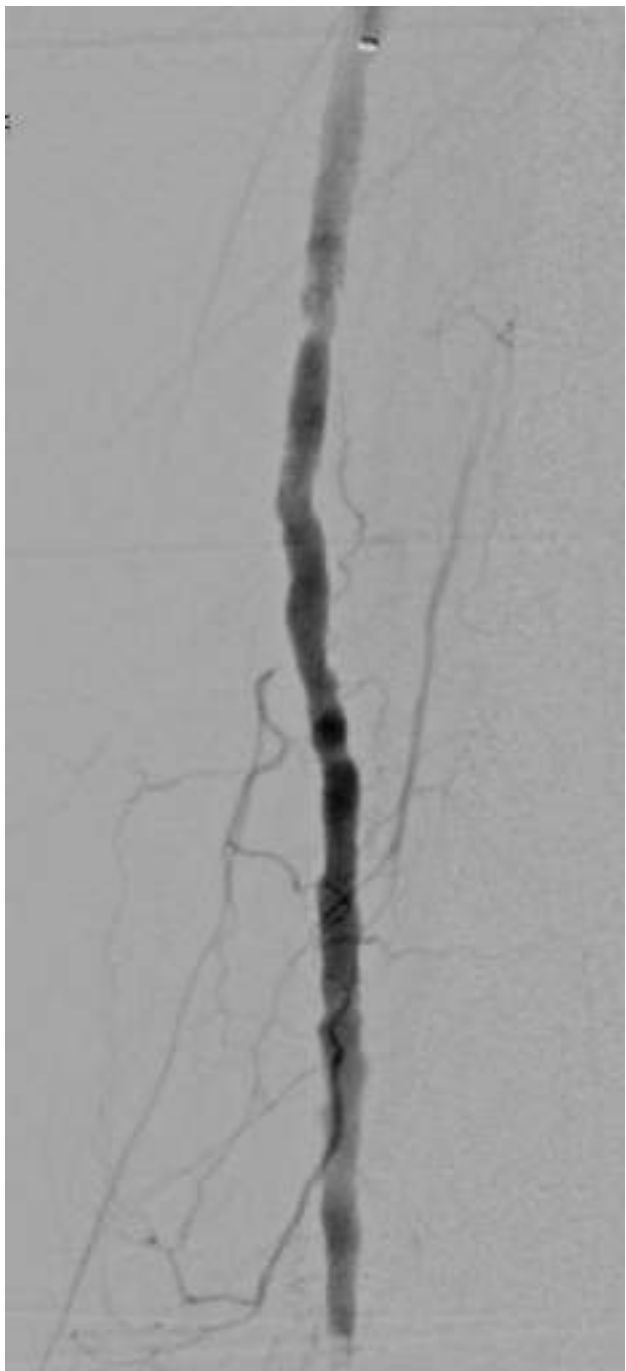


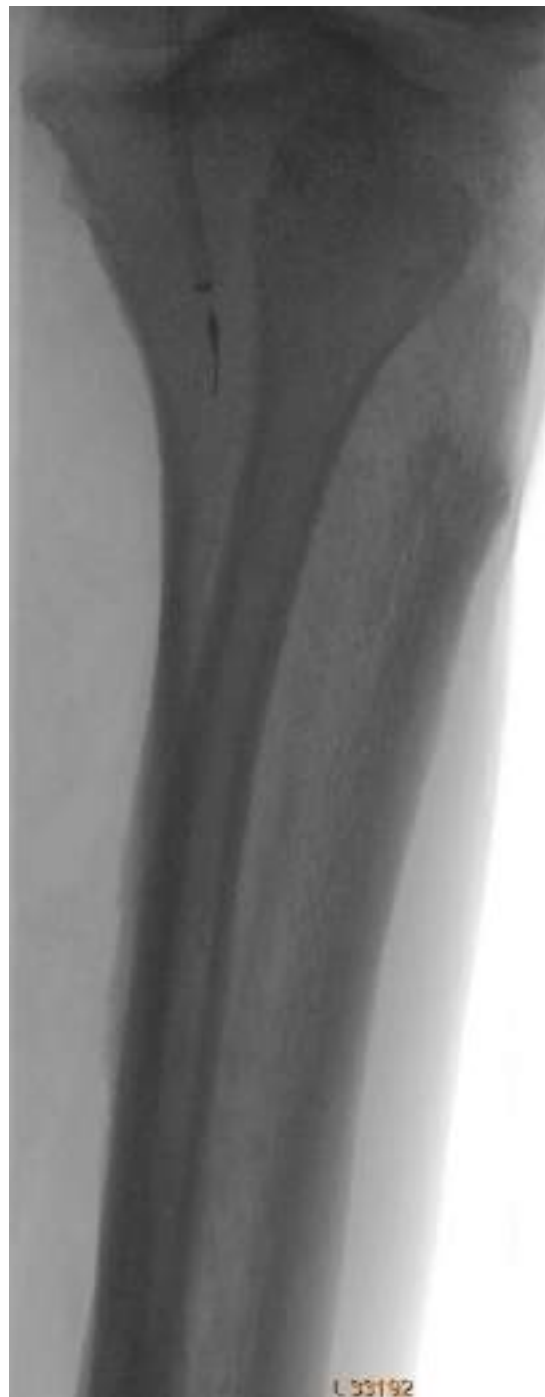
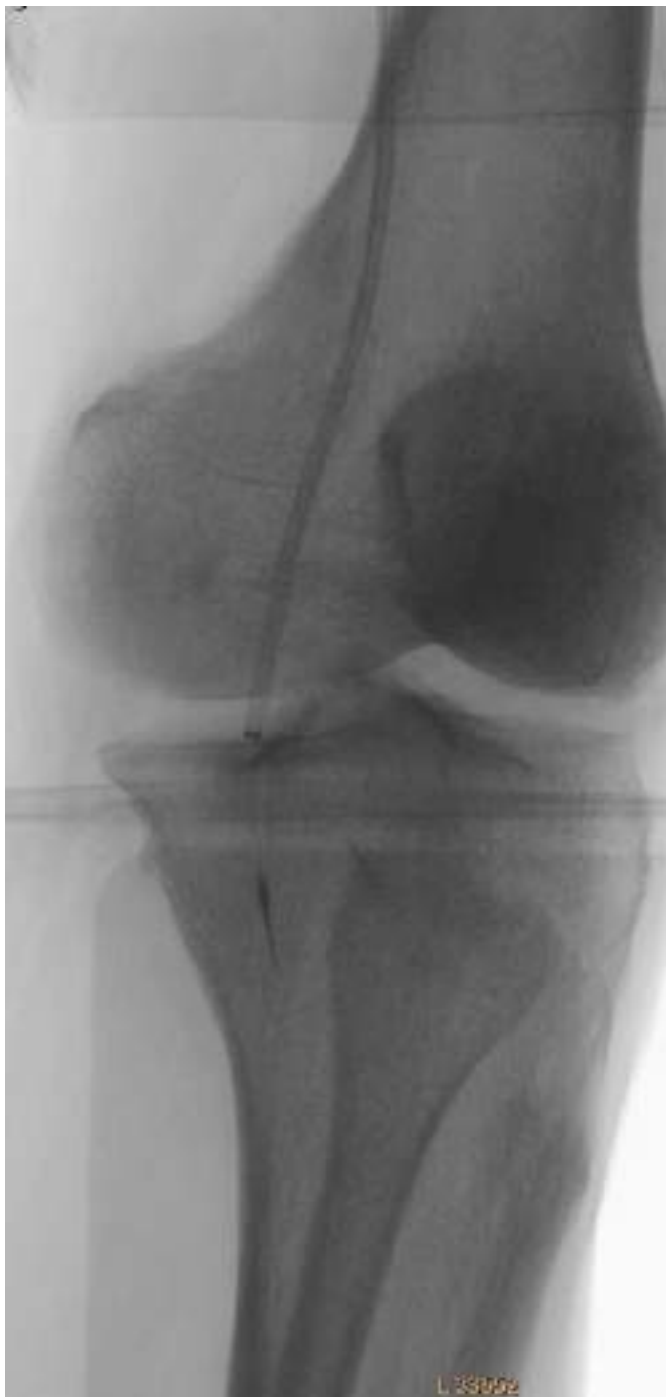


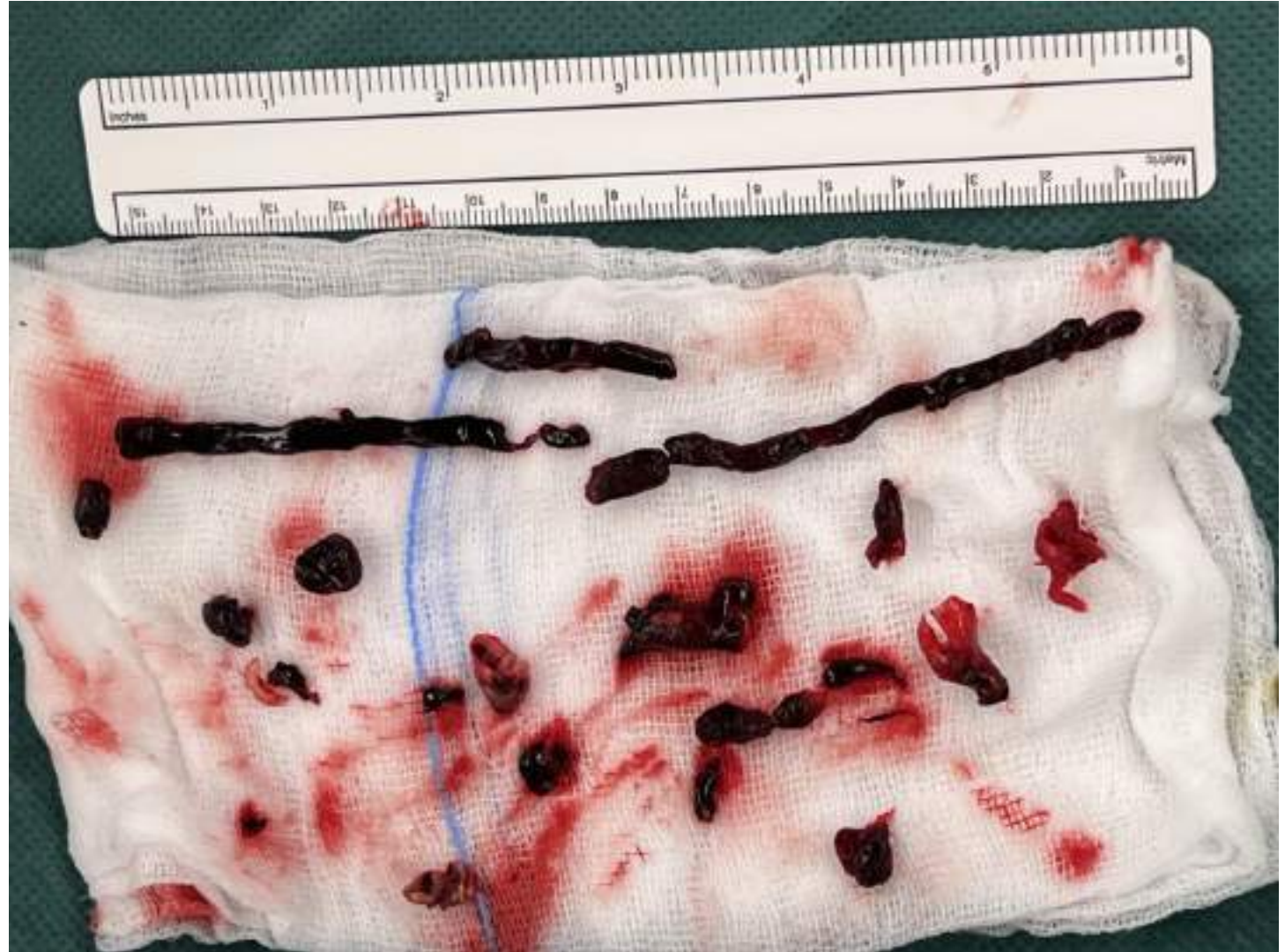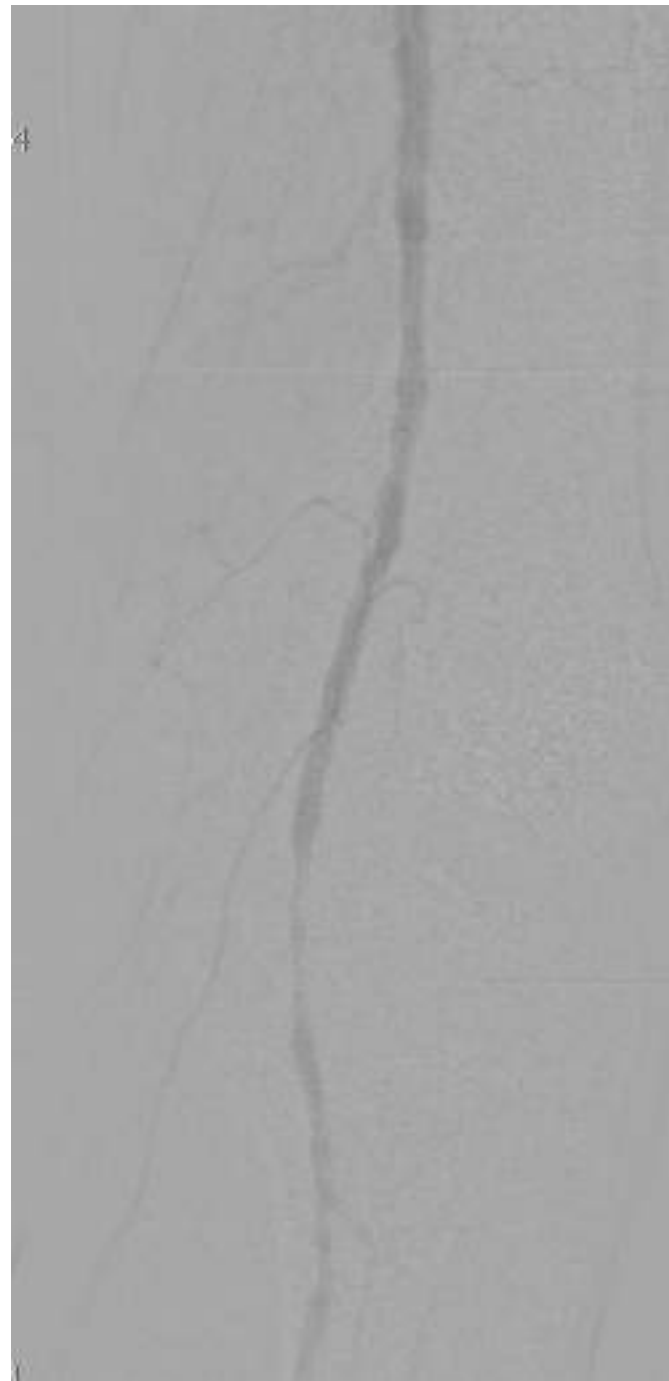
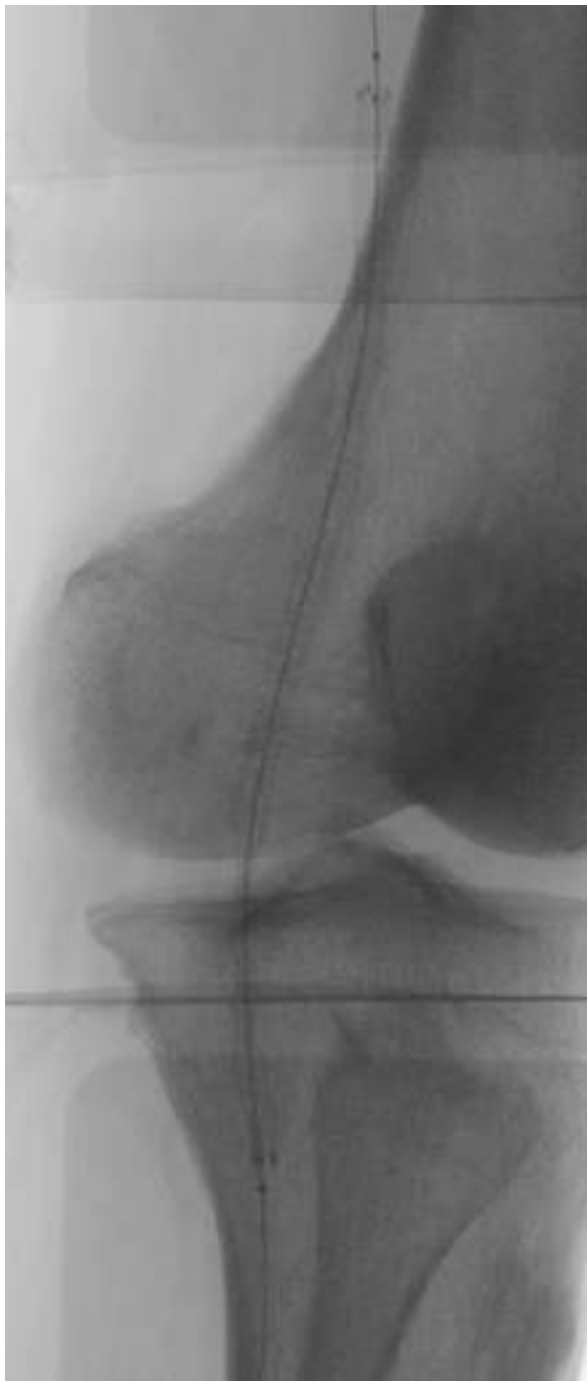



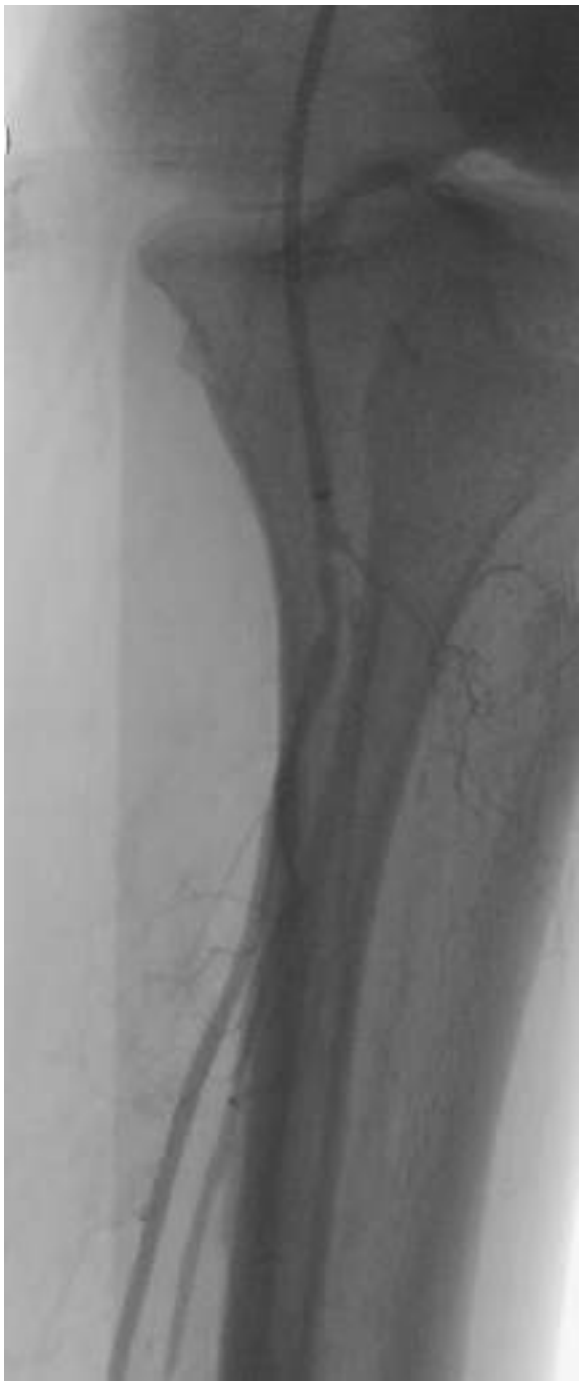
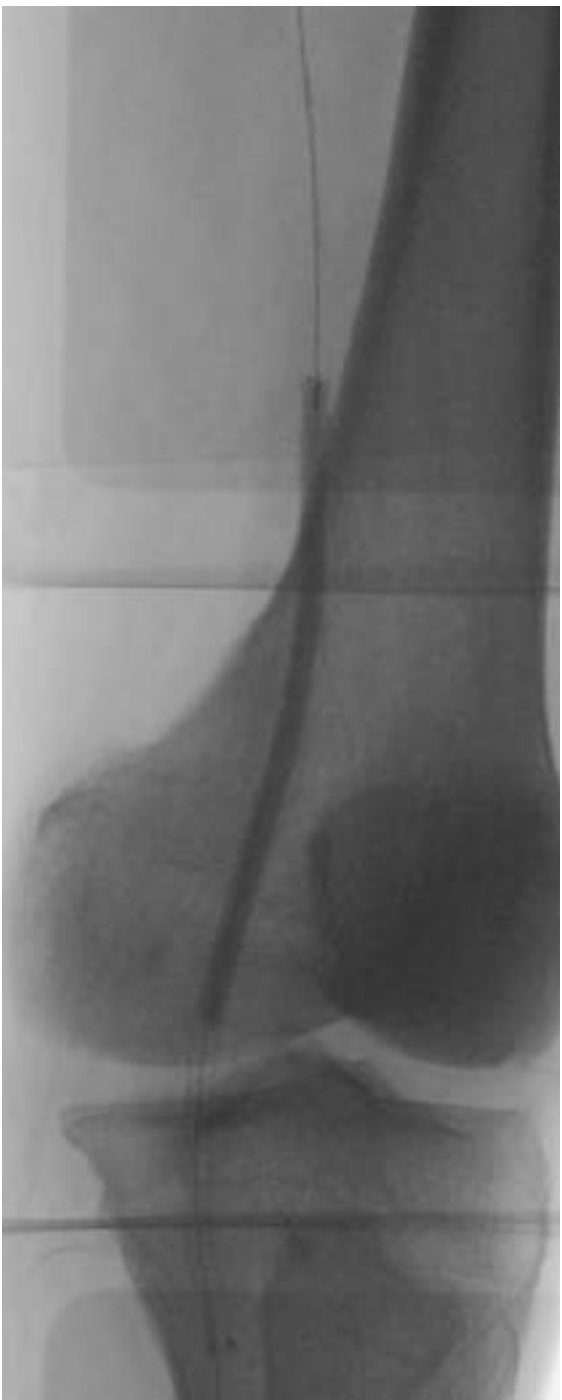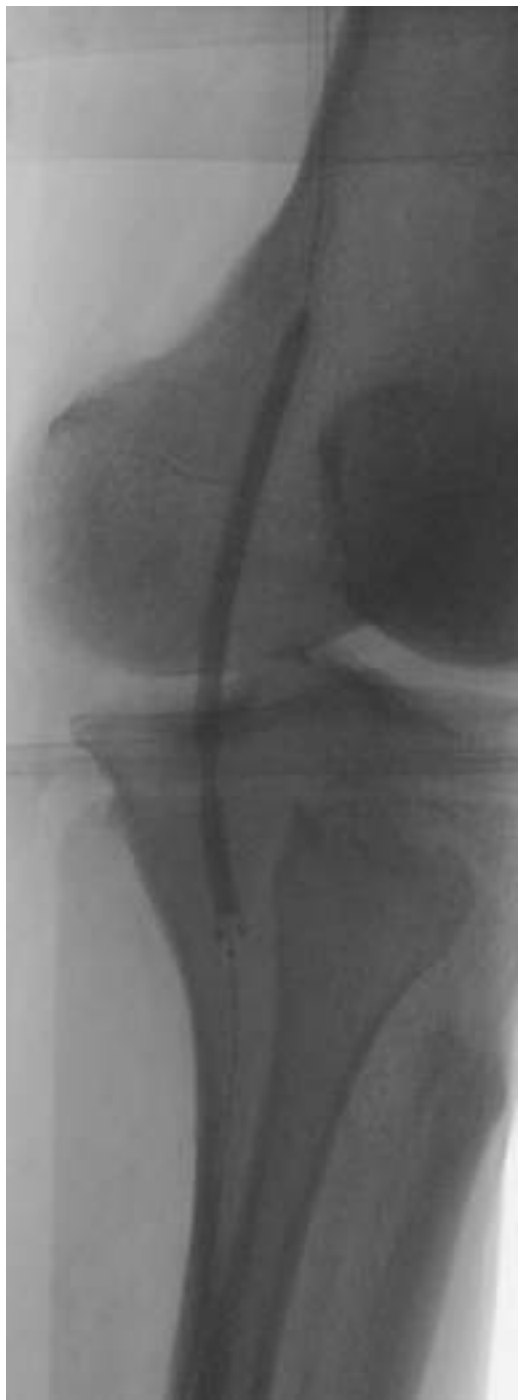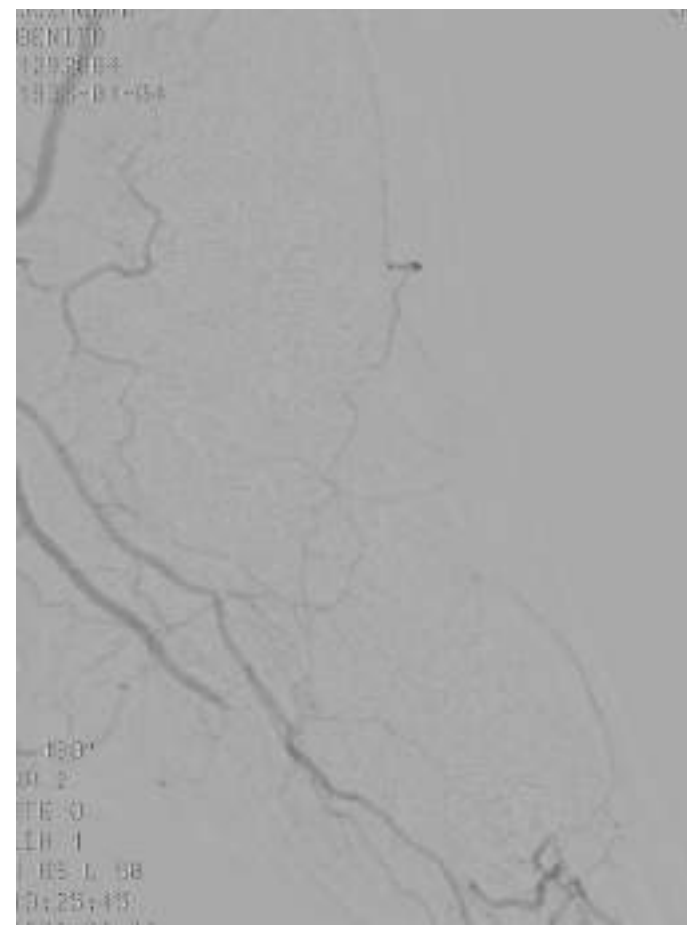
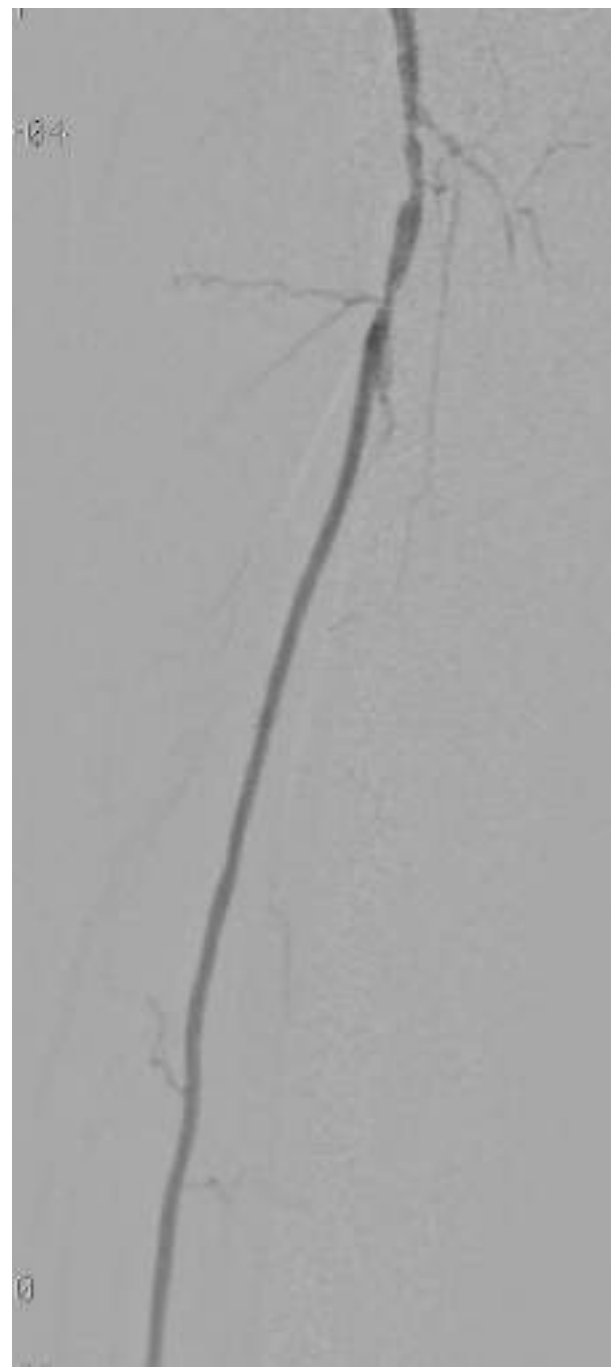
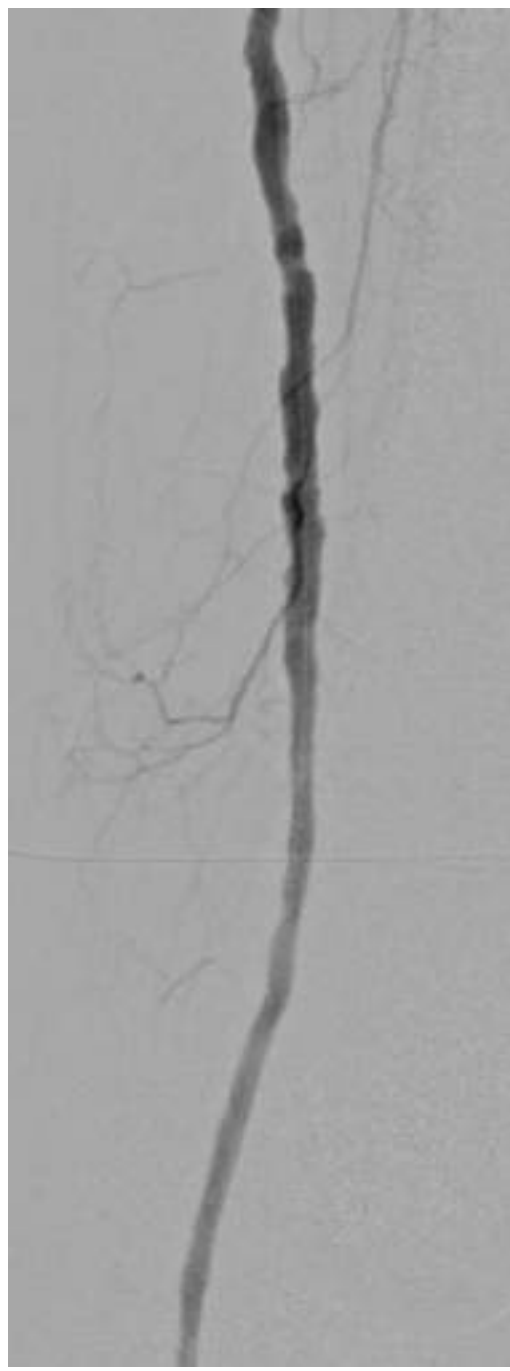
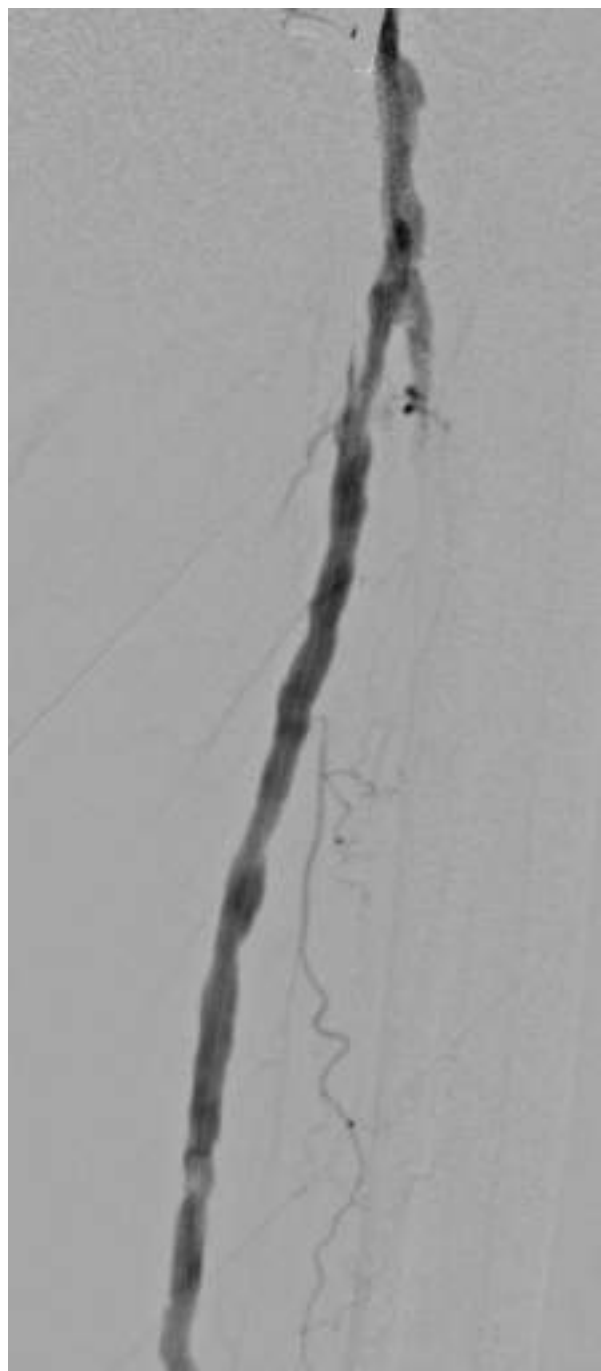


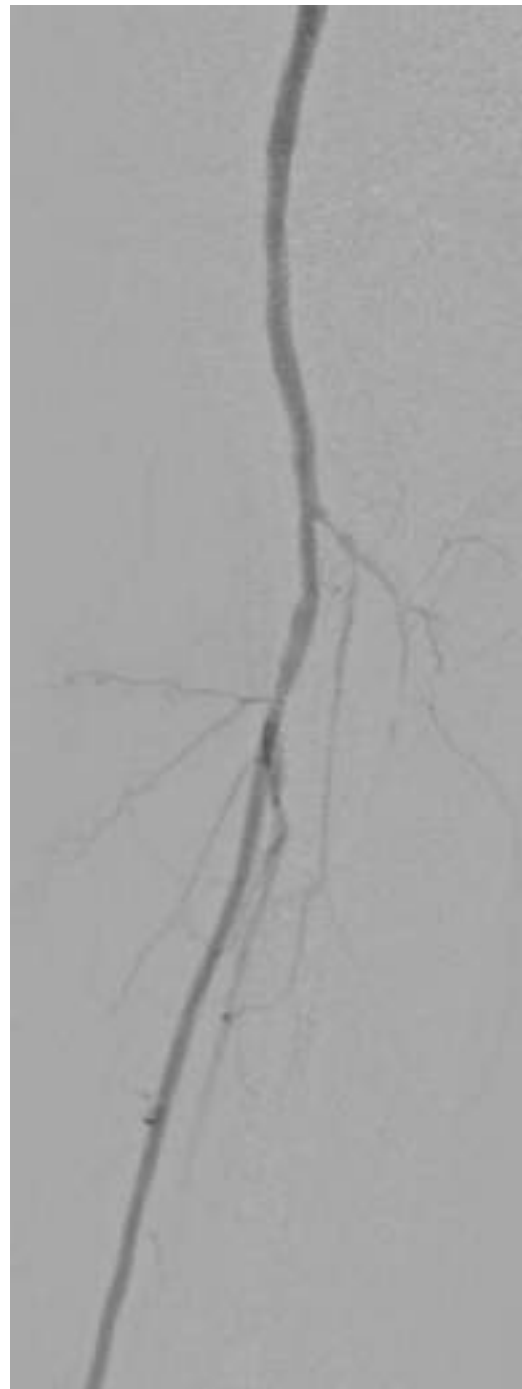
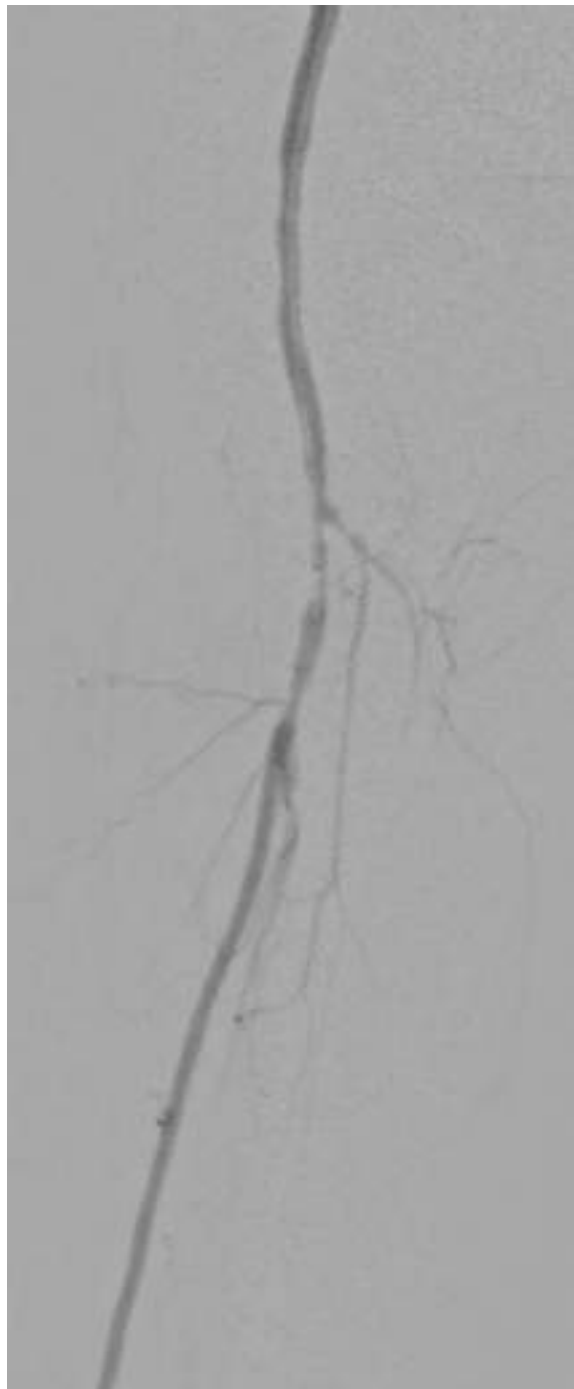


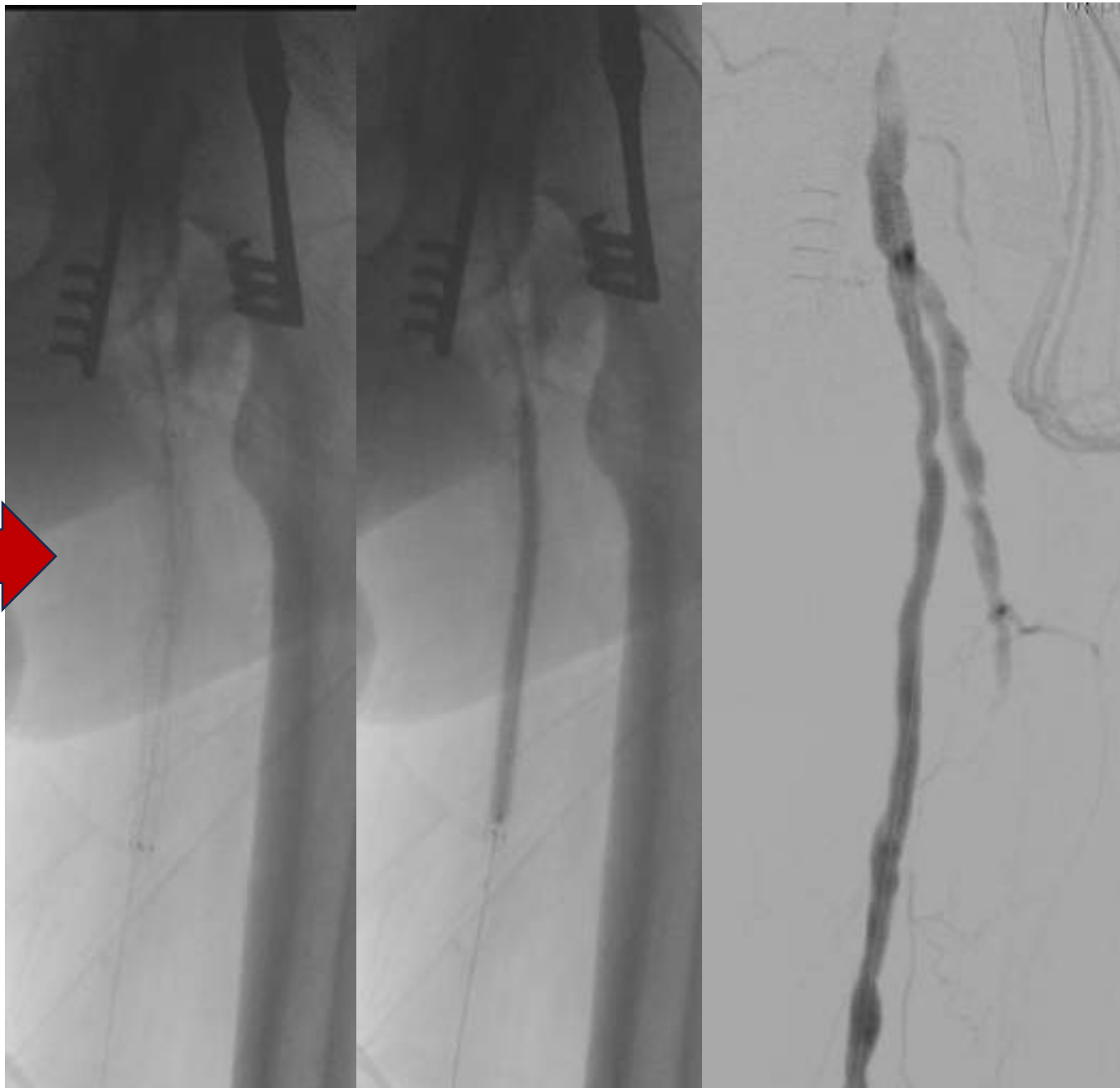

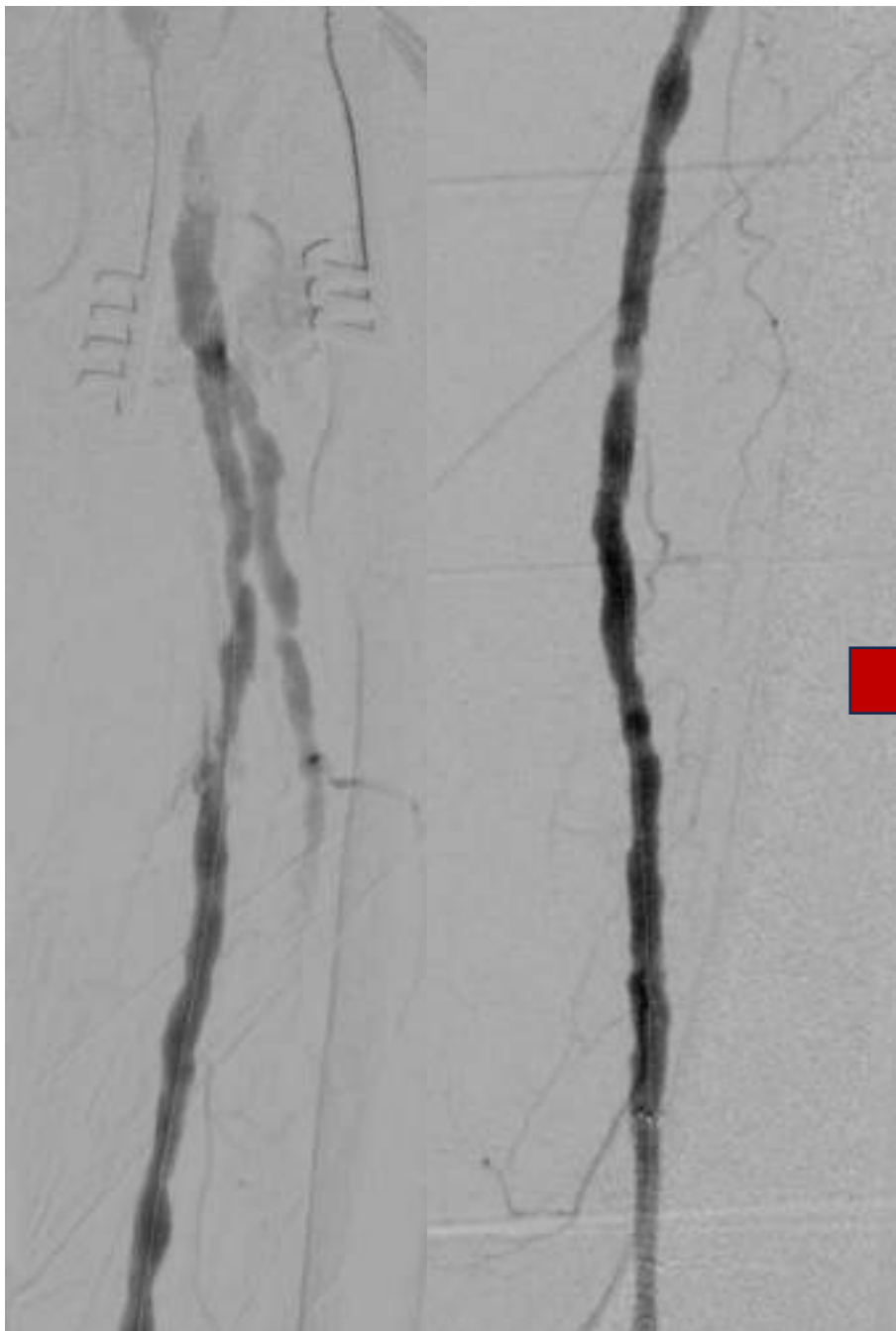


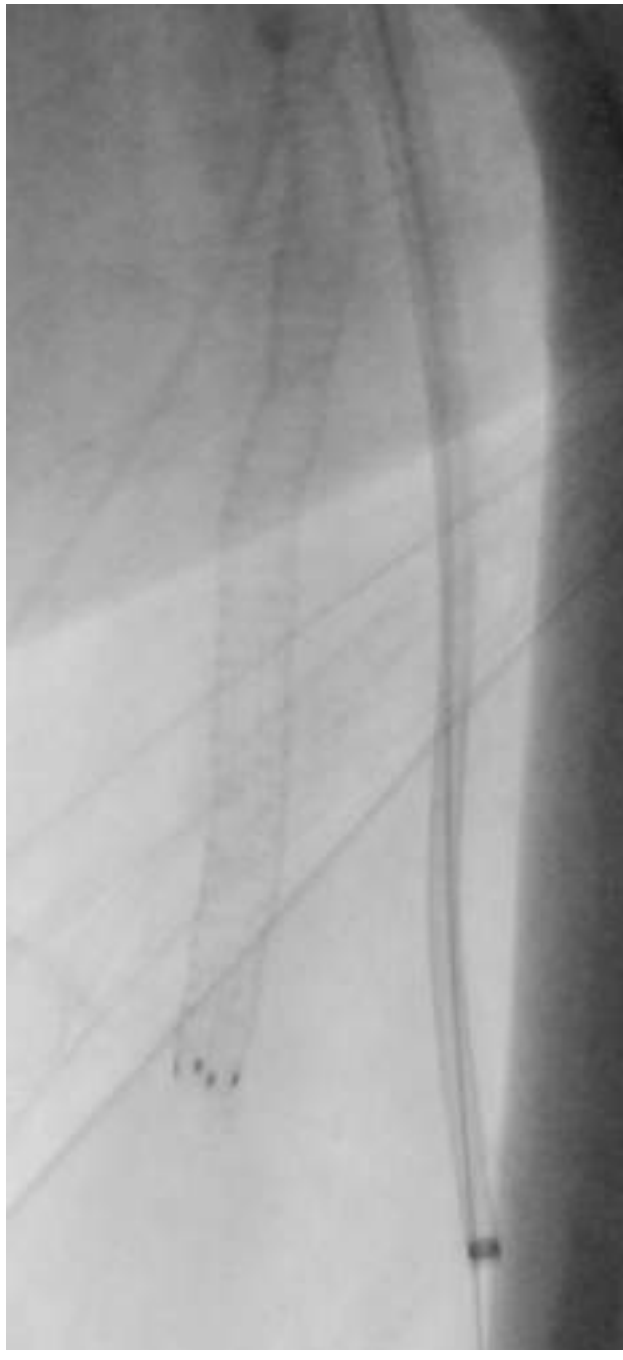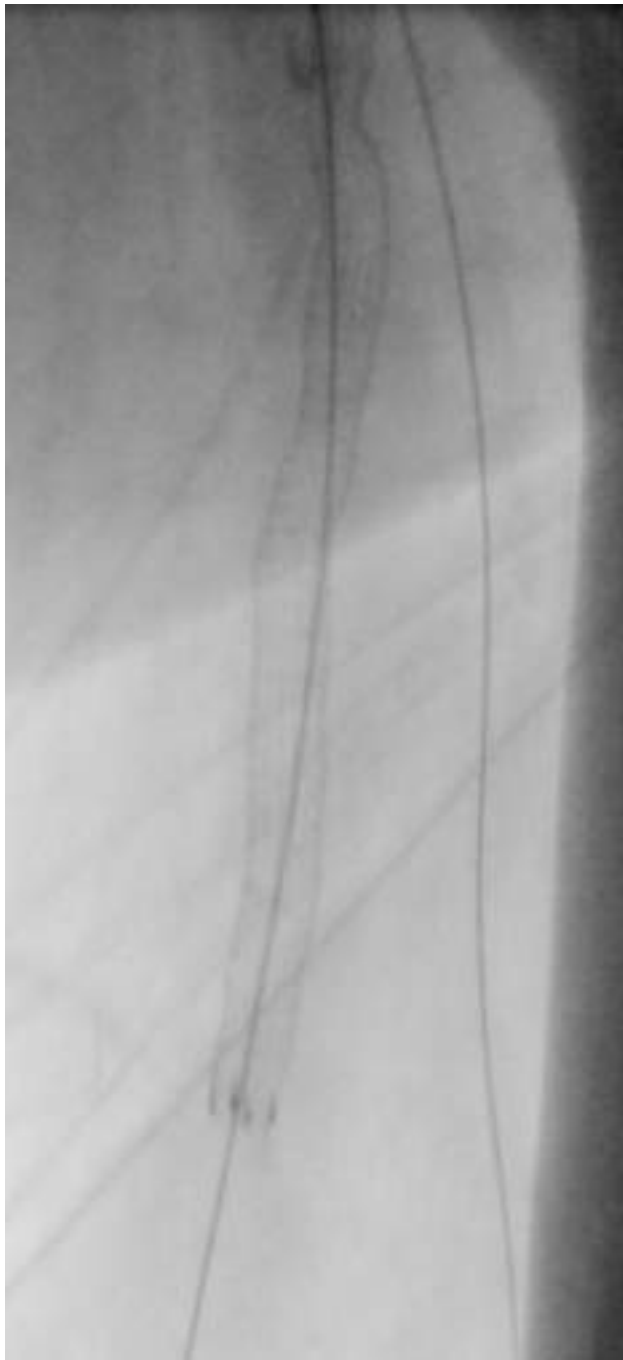


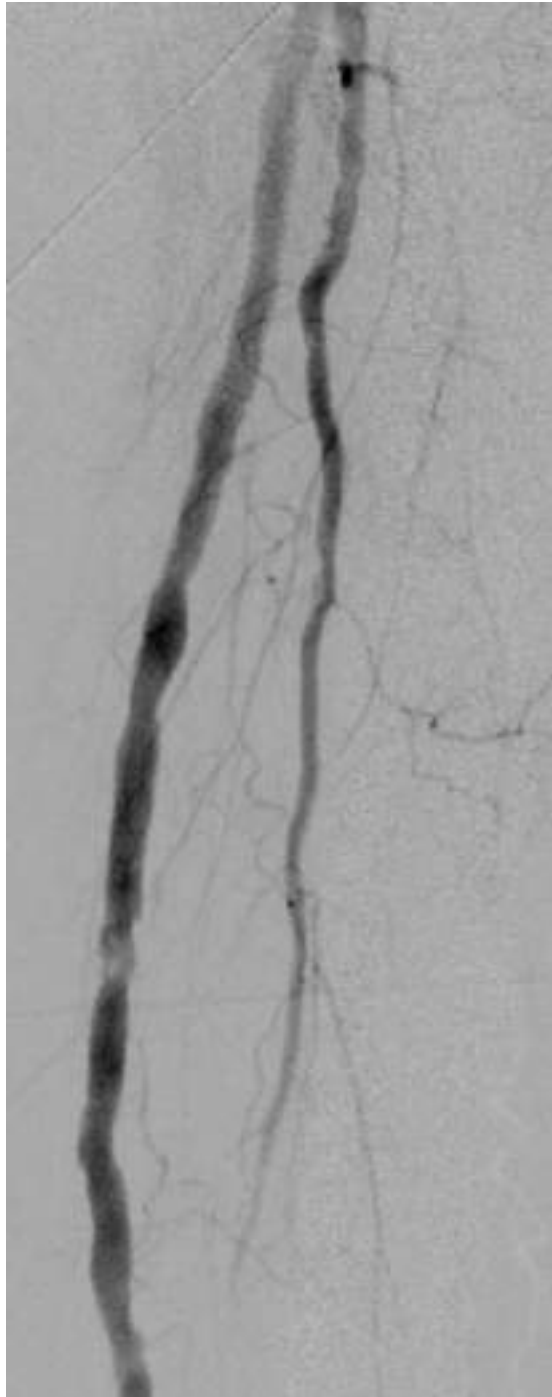
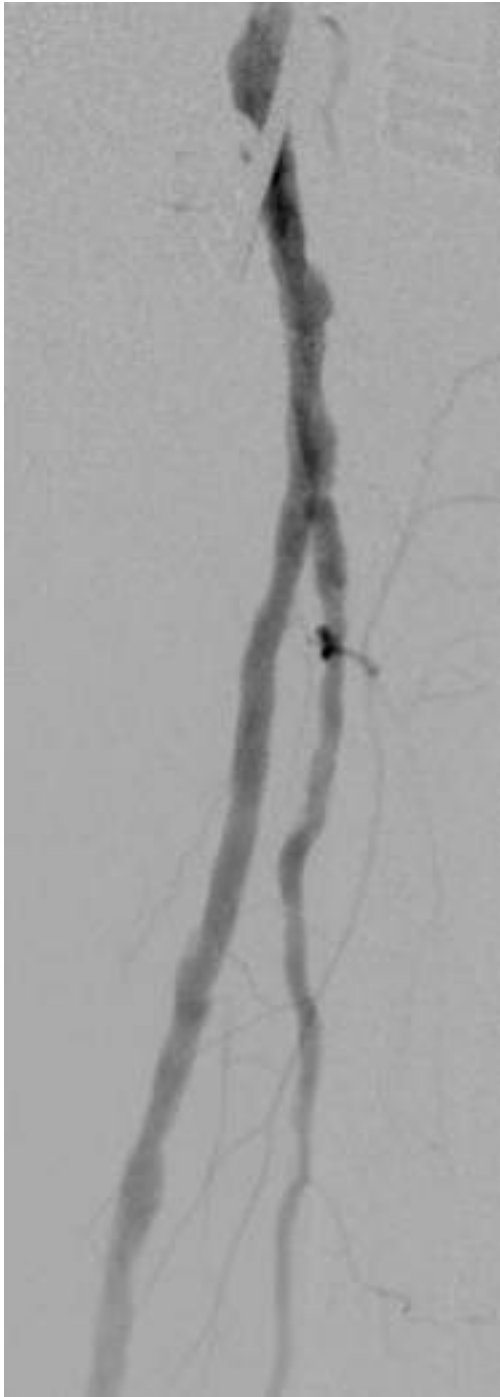


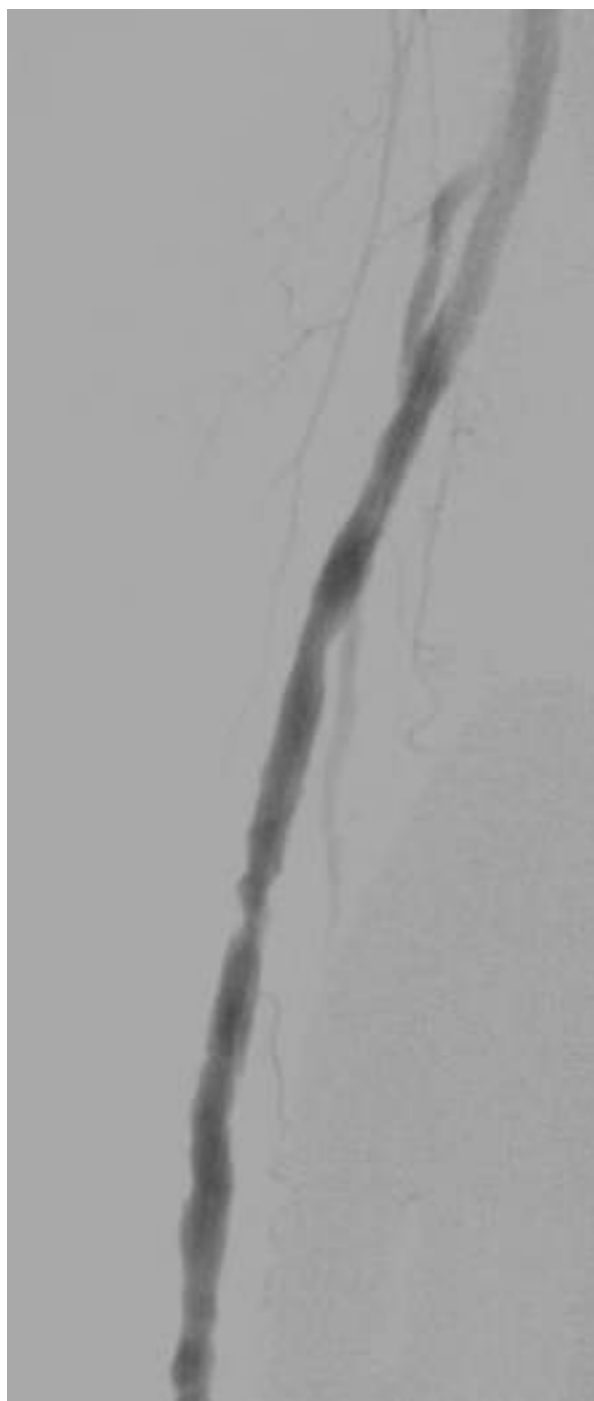
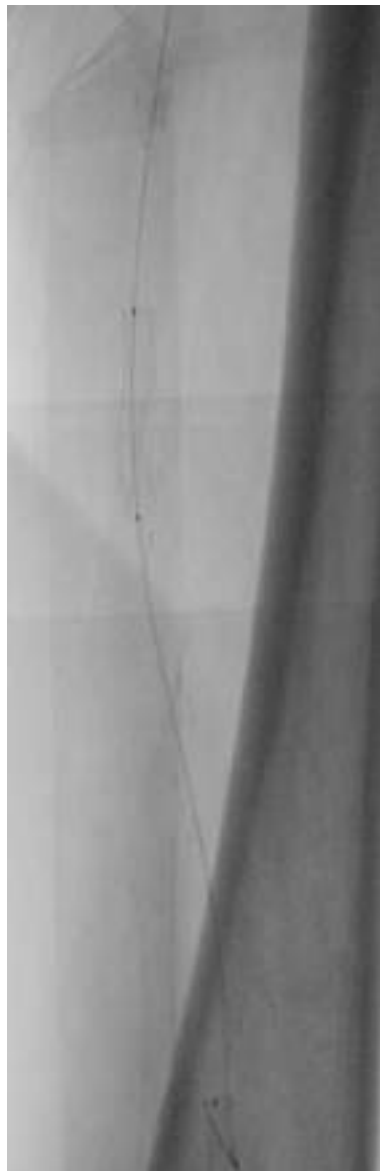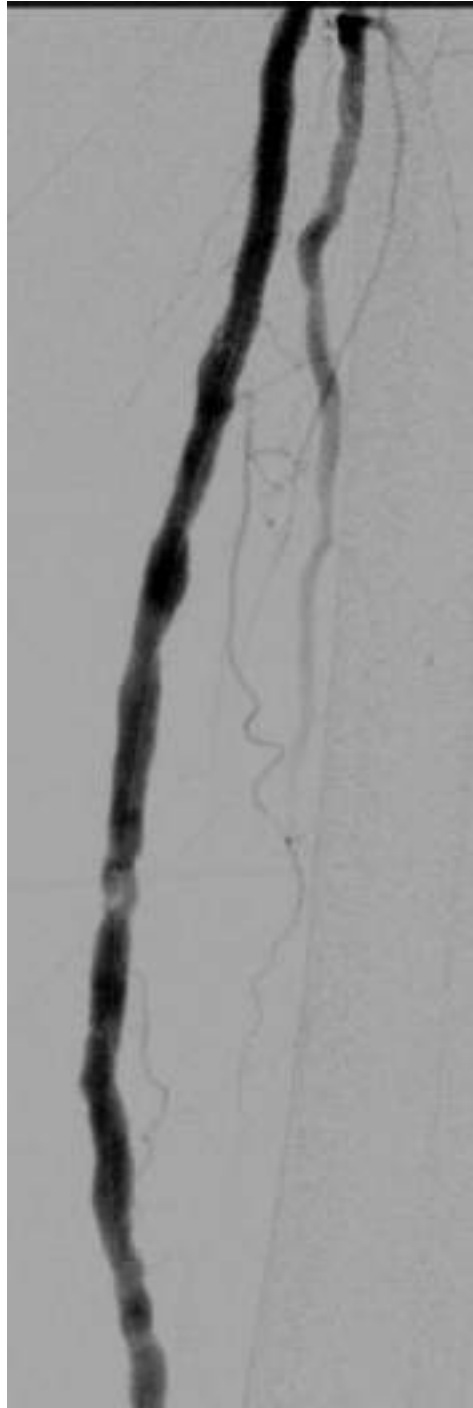












## CASE 2

Female, 65 y.o.

- Atrial fibrillation
- Hypertension
- PAOD: previously multiple left SFA + pop. A. PTA  
PAOD Ruth 5
- 11.04.2022: fem-PTA bypass (in situ saphenous vein)

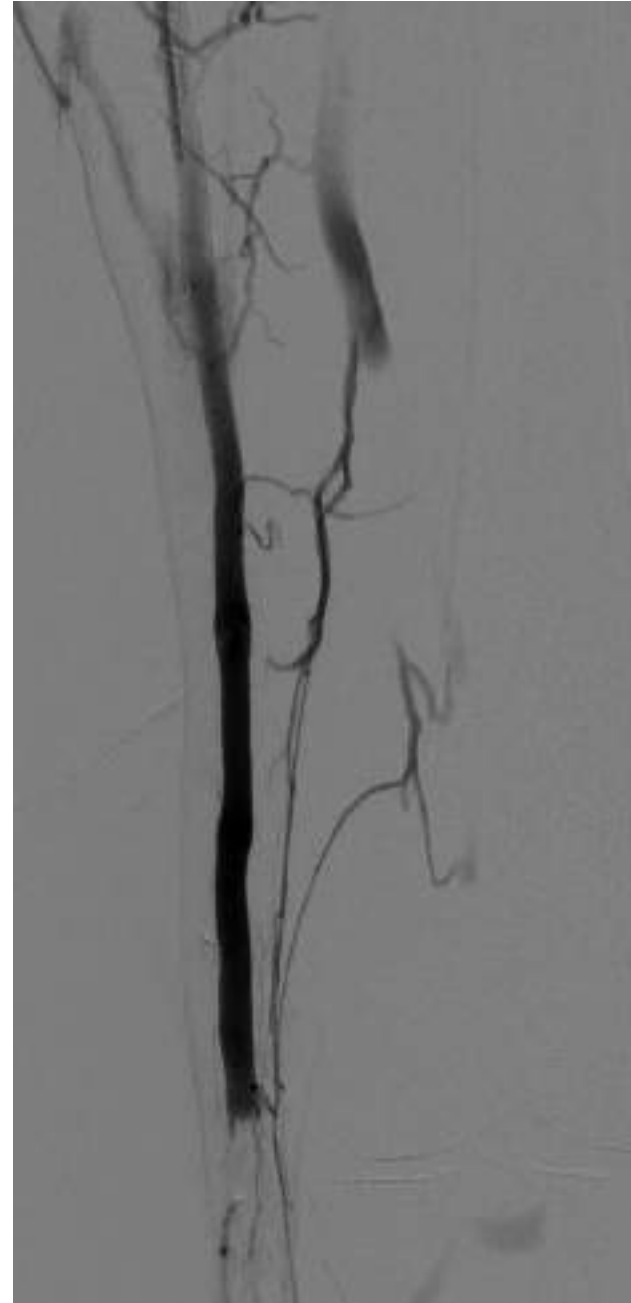
18.04.2022:

Left limb acute pain (distal embolization?)

**EMBOLECTOMY**

18.04.2022:

Bypass and posterior tibial a. occlusion



# LIGHTNING 7 ONE SINGLE PASSAGE



