

ESVS KOL Diabetic Foot Forum

2nd April 2025

Mr David Russell

Associate Professor and Honorary Consultant Vascular Surgeon

University of Leeds / Leeds Teaching Hospitals NHS Trust



Initial presentation

59yr male

Background:

Type 2 diabetes on insulin (HbA_{1c} 72)

Depression

Previous right CLTI with 4th toe ulceration

Right SFA and AT angioplasty April 2023

Smoker

Drug history:

Insulin (Humulin M3), metformin, gliclazide

Aspirin, atorvastatin

Initial presentation 26th January 2024

Presented acutely

New left foot neuroischaemic ulceration with secondary infection

1 week history

On examination:

Systemically well

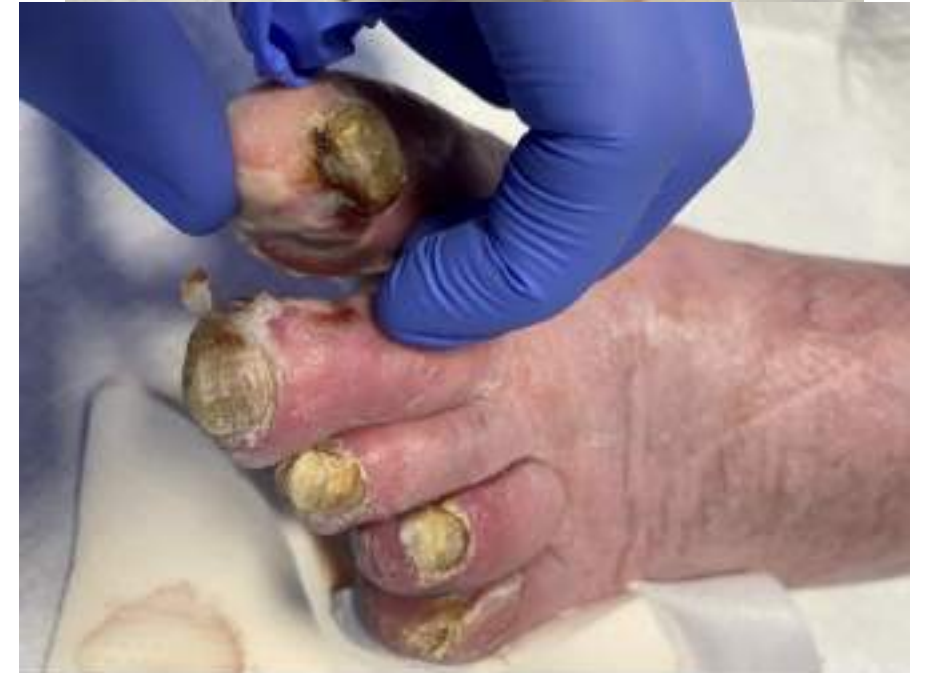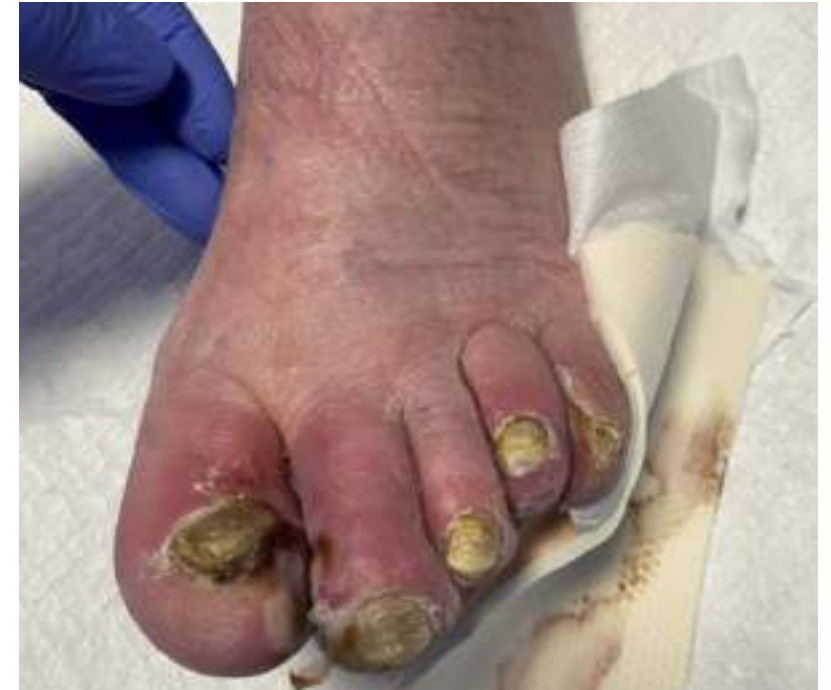Ischaemic lesions to 1st, 2nd, 4th and 5th toes

left femoral and popliteal pulse palpable

no pedal pulses

Bloods:

WCC 11.5; CRP 25



Initial plan

X-ray foot

WCC

Angio if toe pressure reduced (not measured)

Antibiotics for possible osteomyelitis

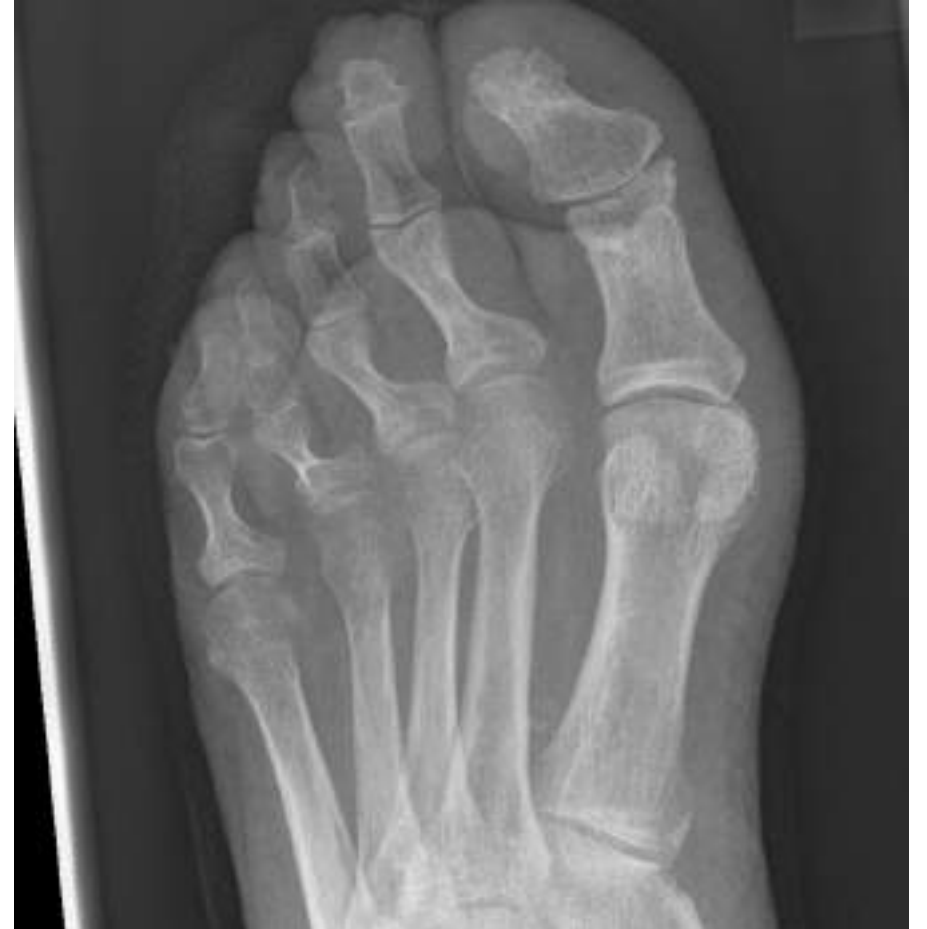Following day:

Toe pressure/HHD not assessed

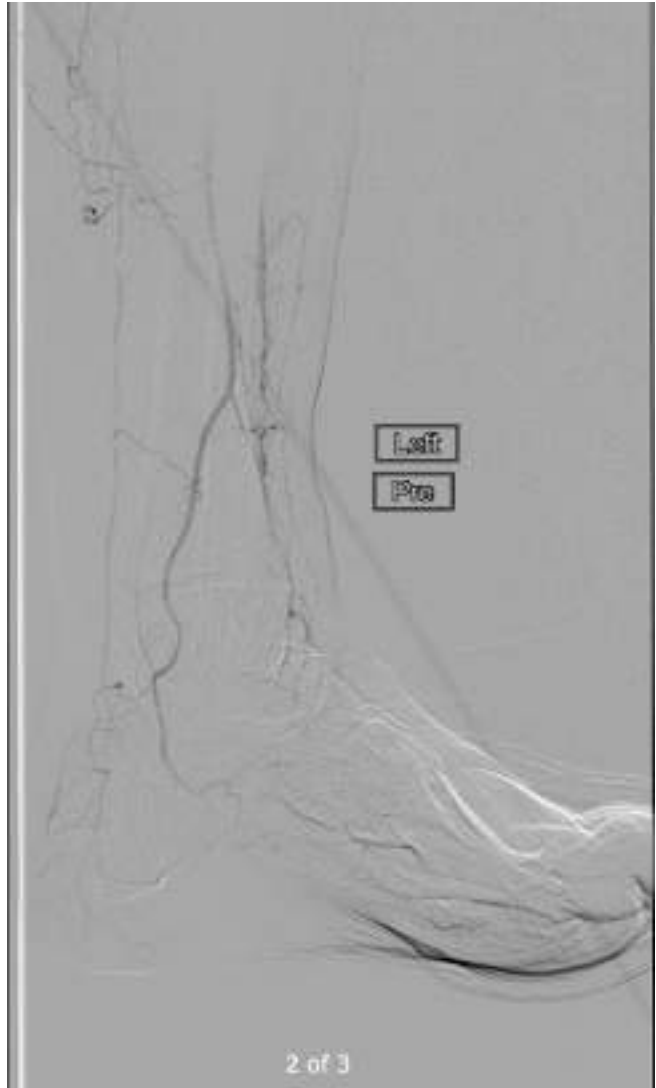
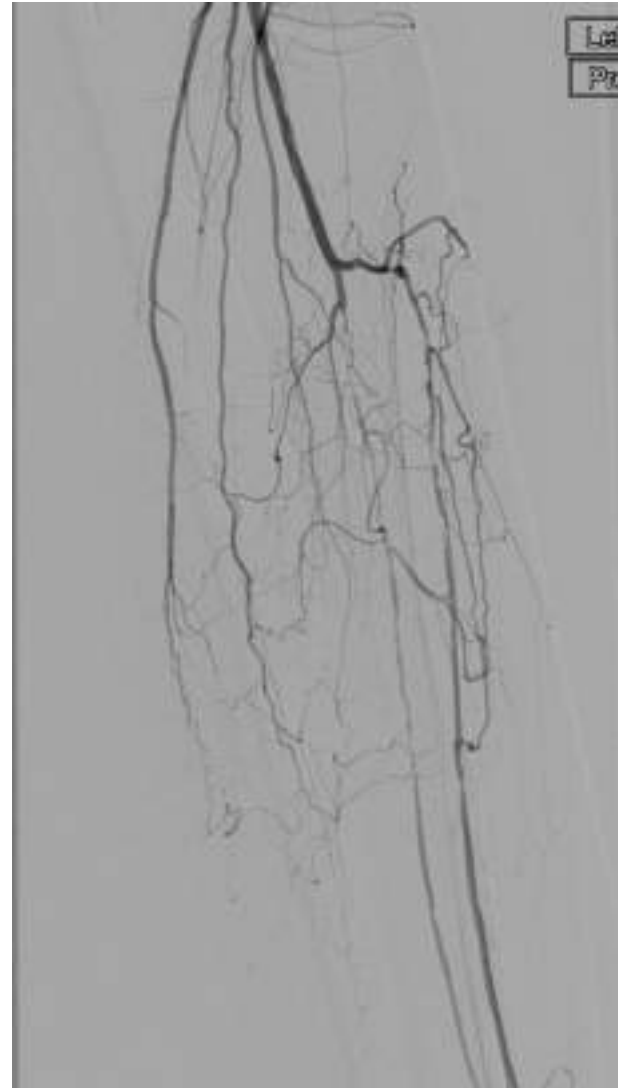
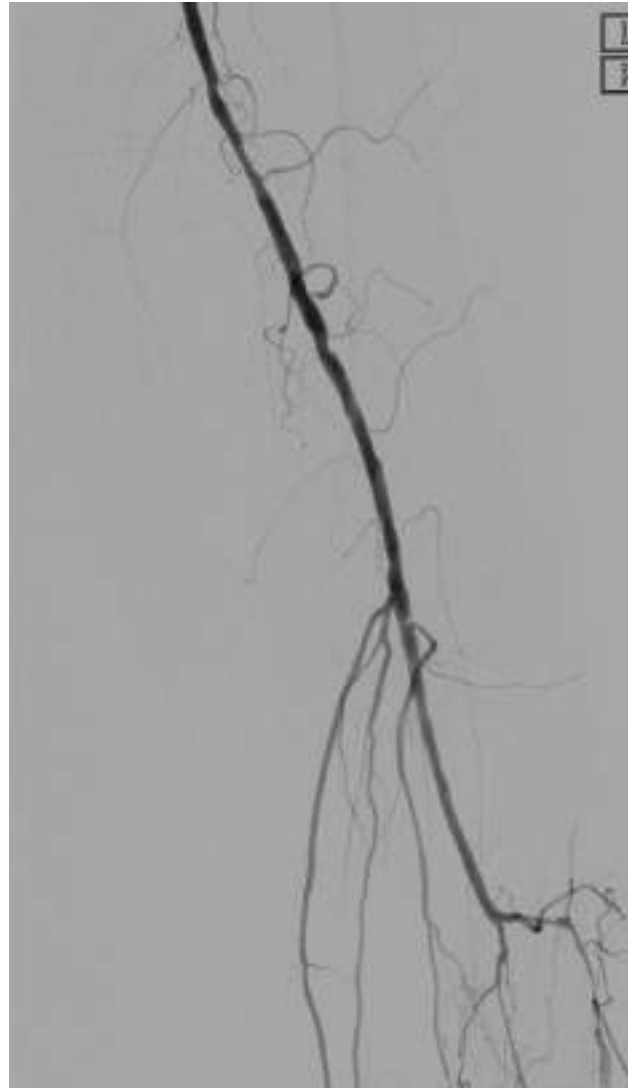
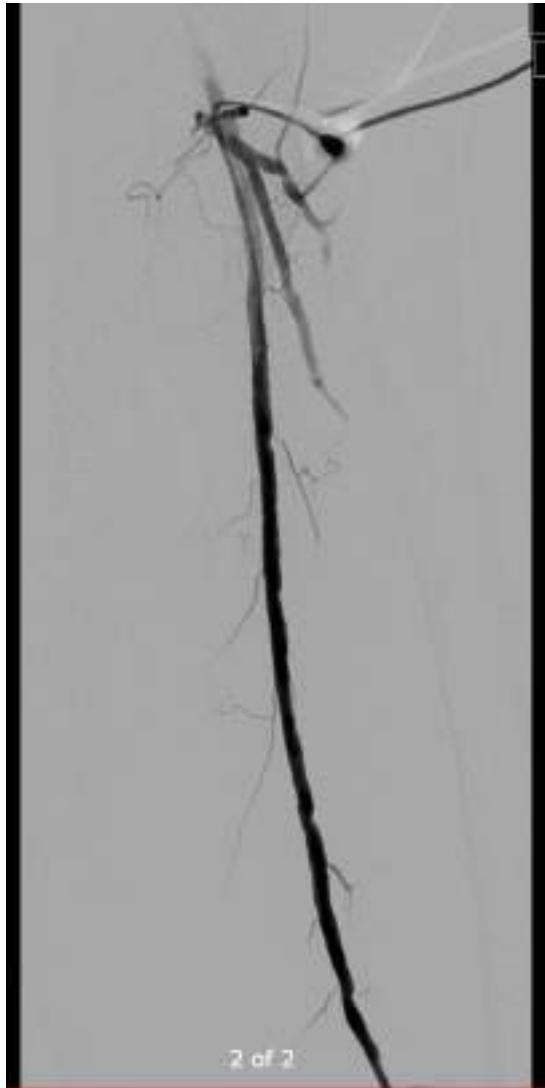
Straight to diagnostic angio +/- proceed

Previous vein map: Left GSV 2.7-3.5mm (<3mm from mid-thigh)

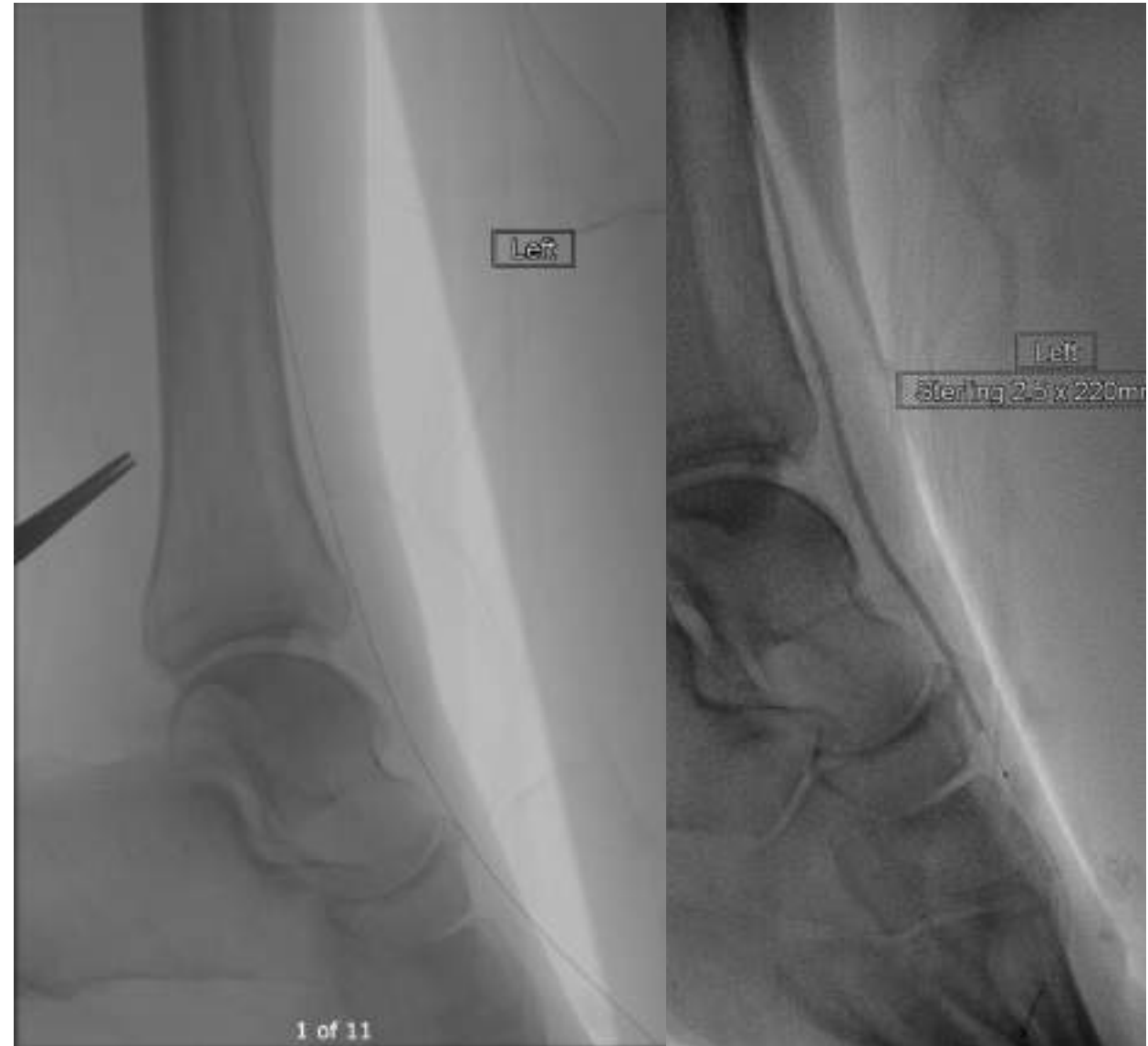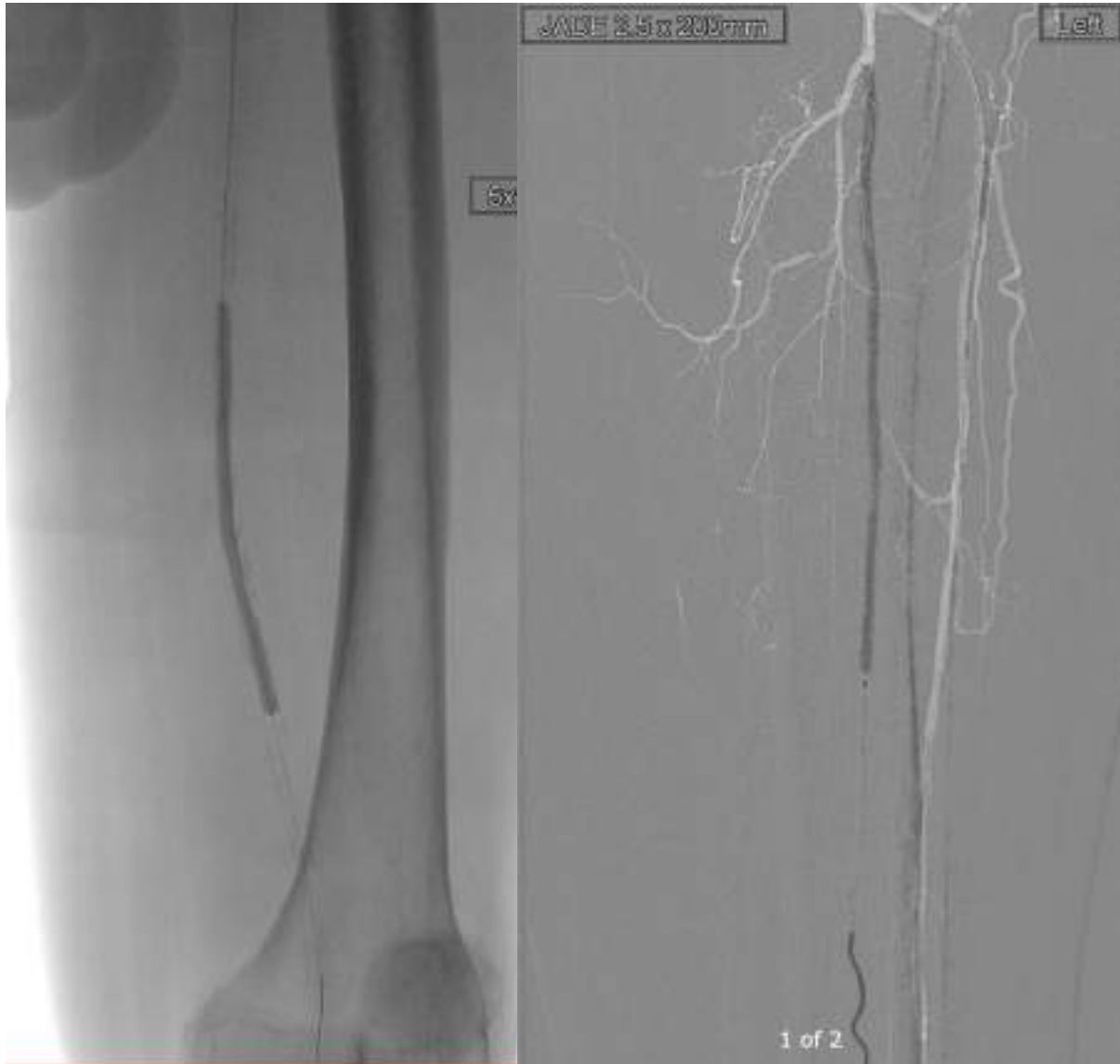Previous ECHO: EF 55-60%



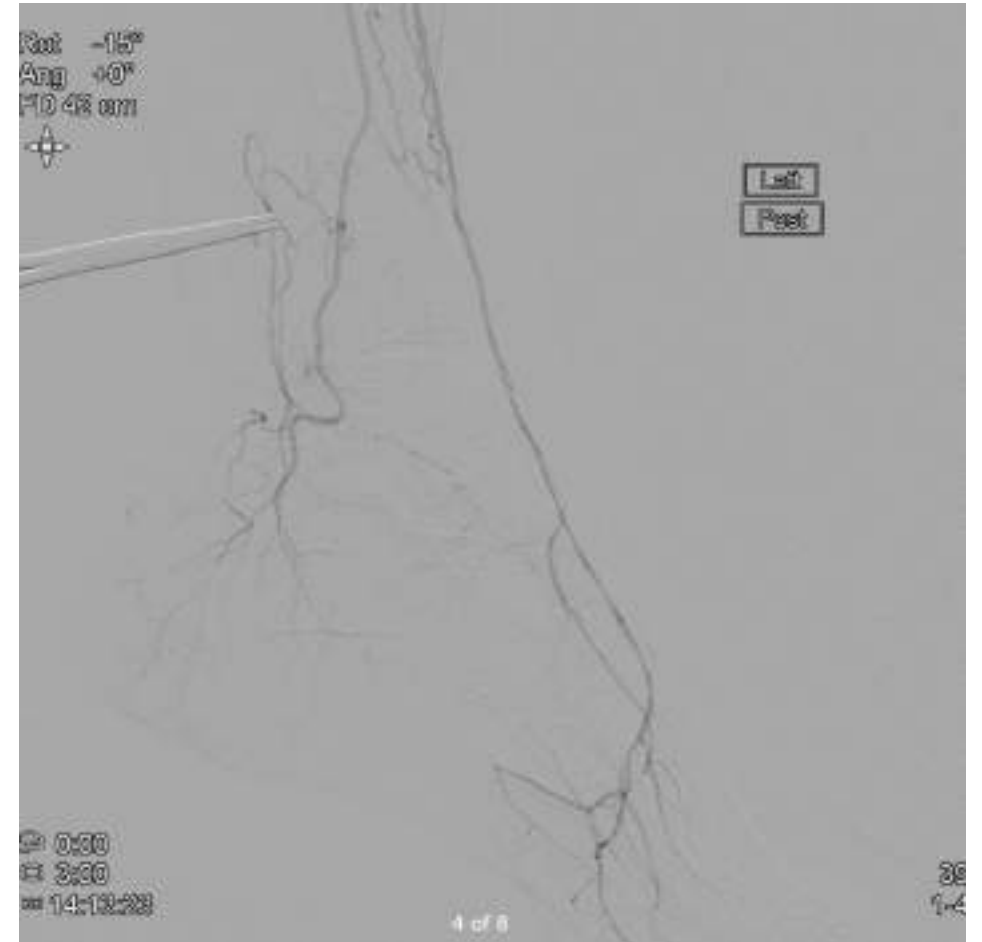
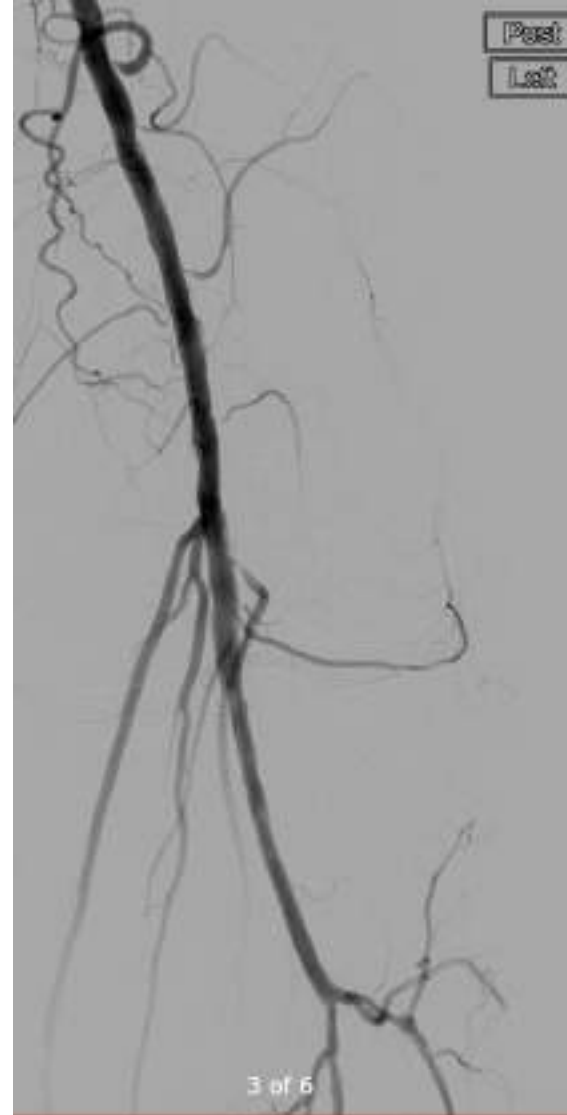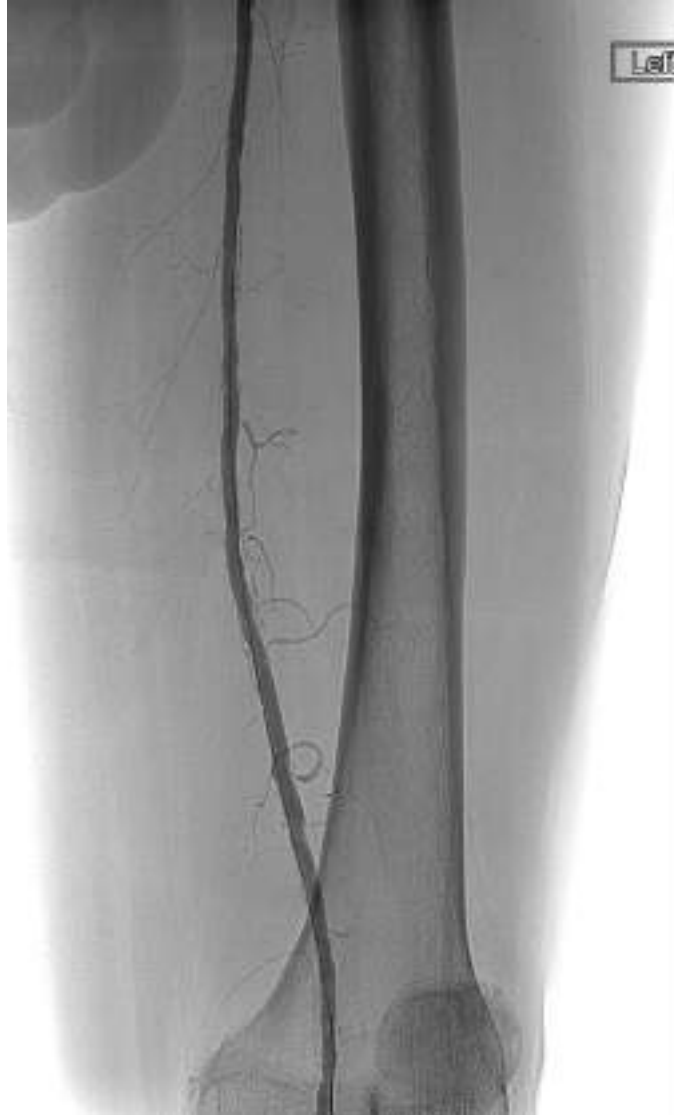Angiogram



Angiogram - procedure



Angiogram - result



Deterioration 7th May 2024

Seen as an urgent self-referral

Deterioration in left 5th toe with new 5th MT head lateral ulcer

Repeat toe pressure 31mmHg

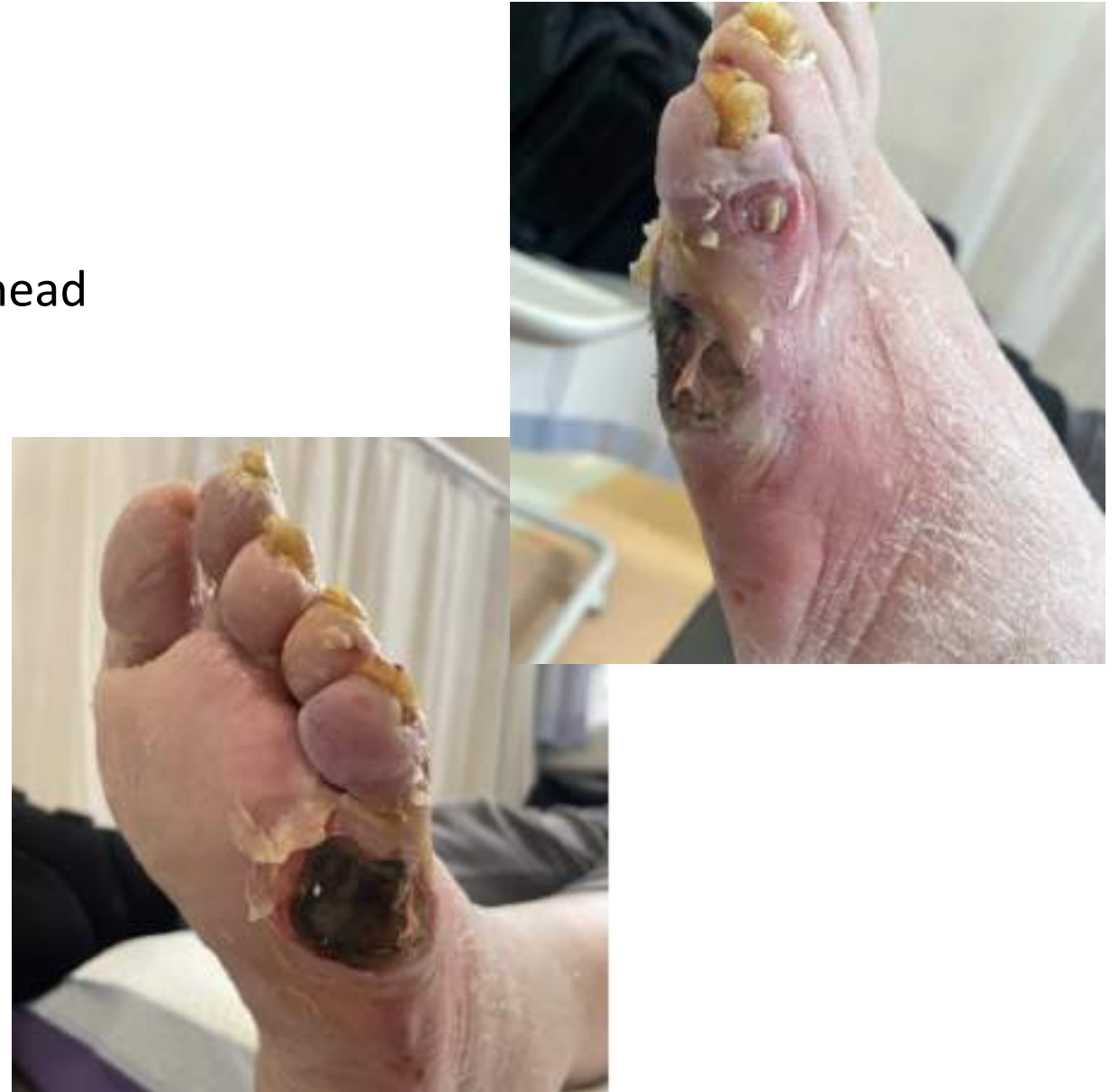Clinically infected

Probes to bone

WIFI stage 4, high benefit revasc

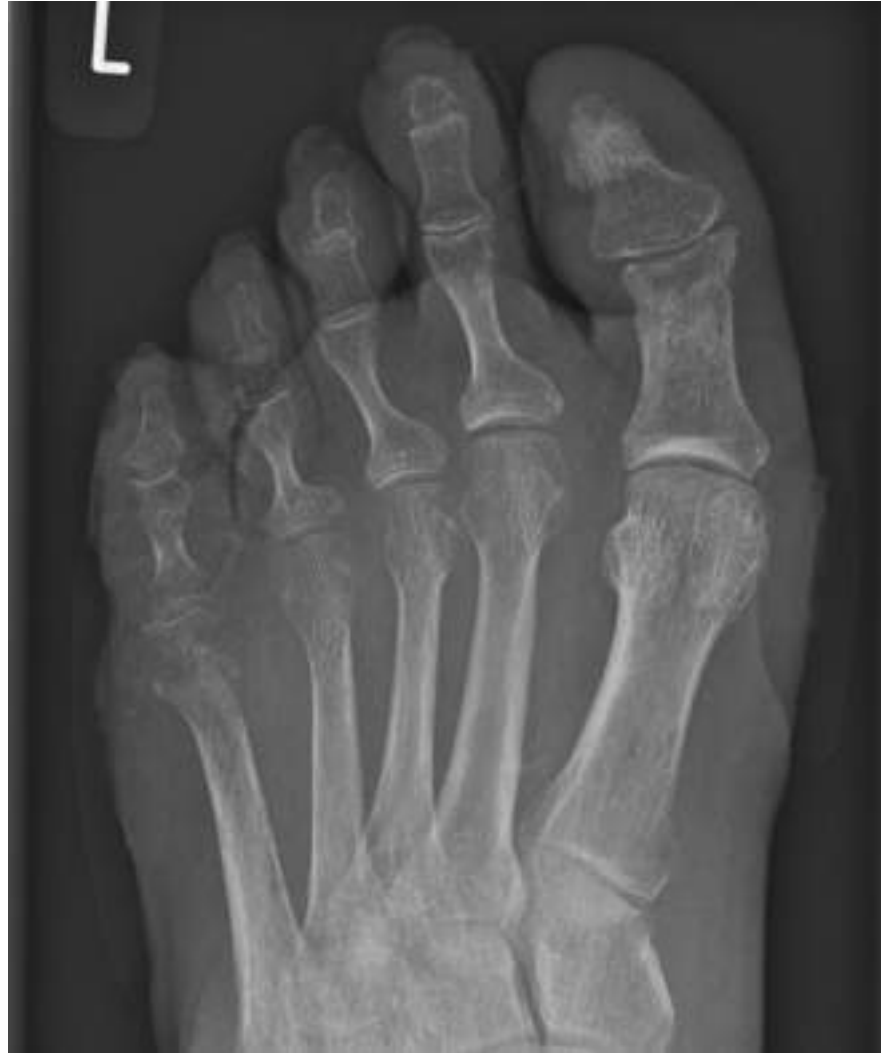Foot X-ray

Empirical antibiotics for osteomyelitis



Imaging

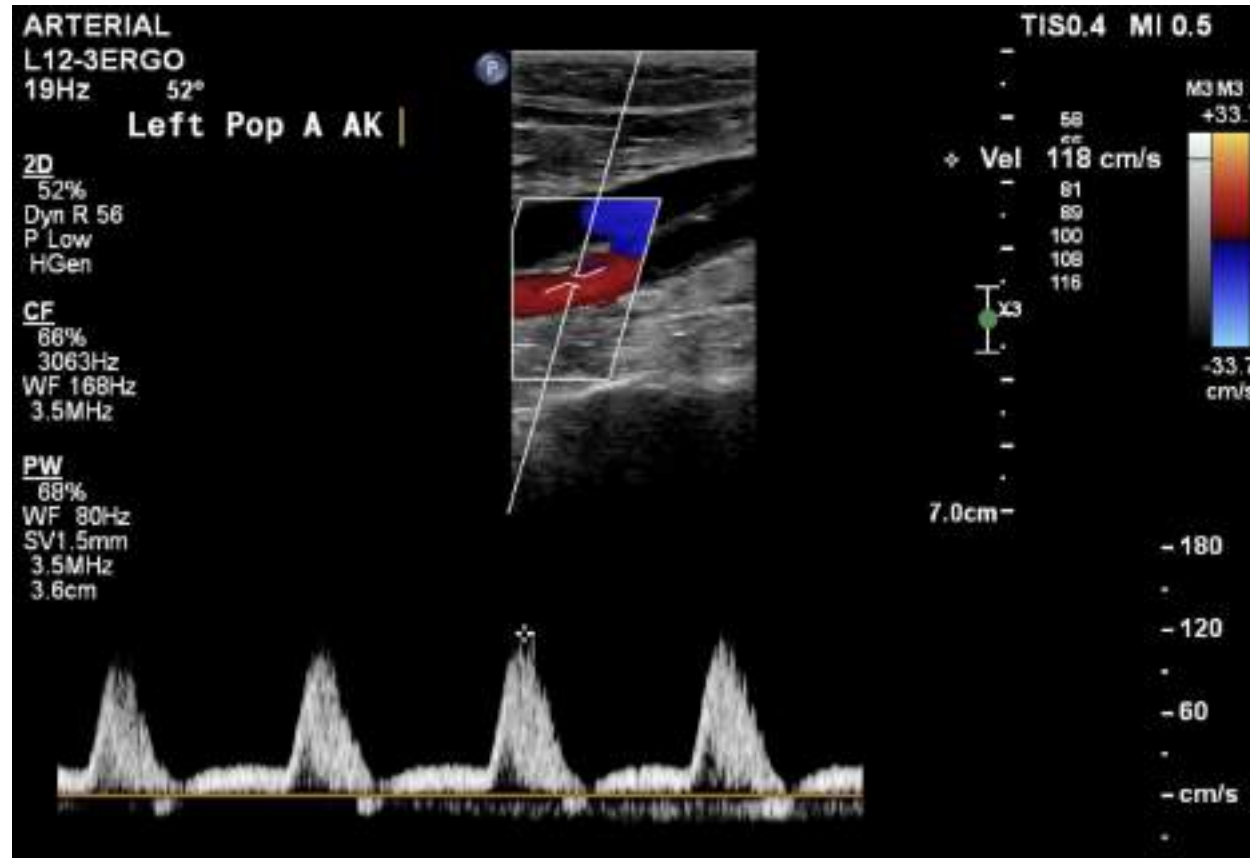
Foot X-ray



Imaging

Foot X-ray

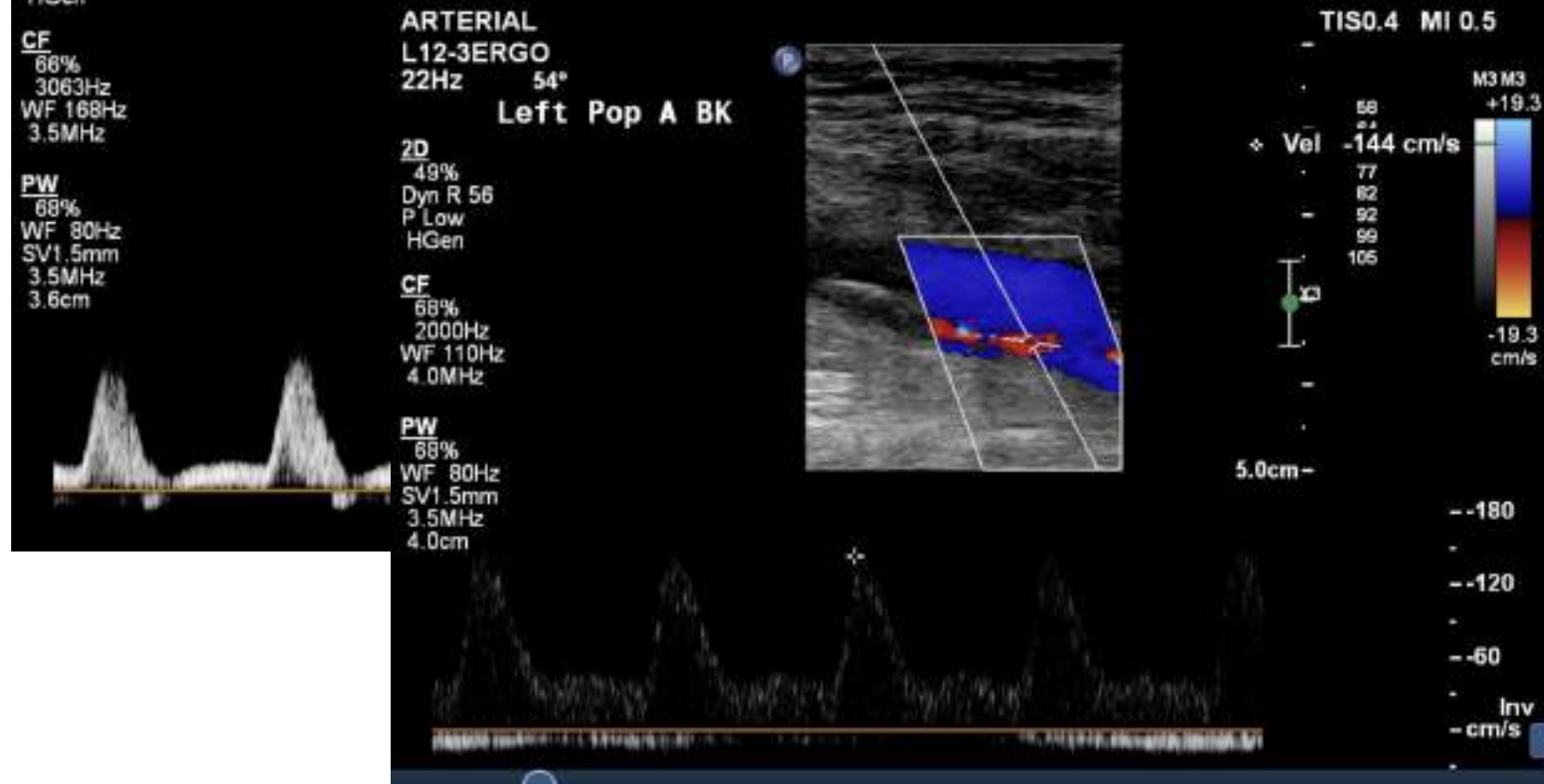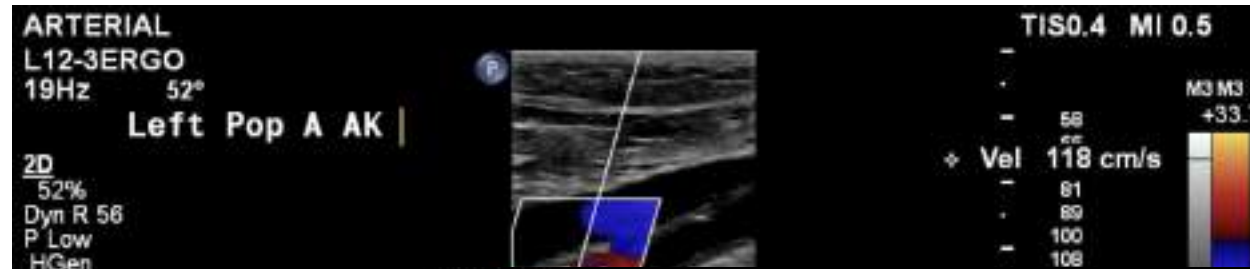
Arterial Duplex



Imaging

Foot X-ray

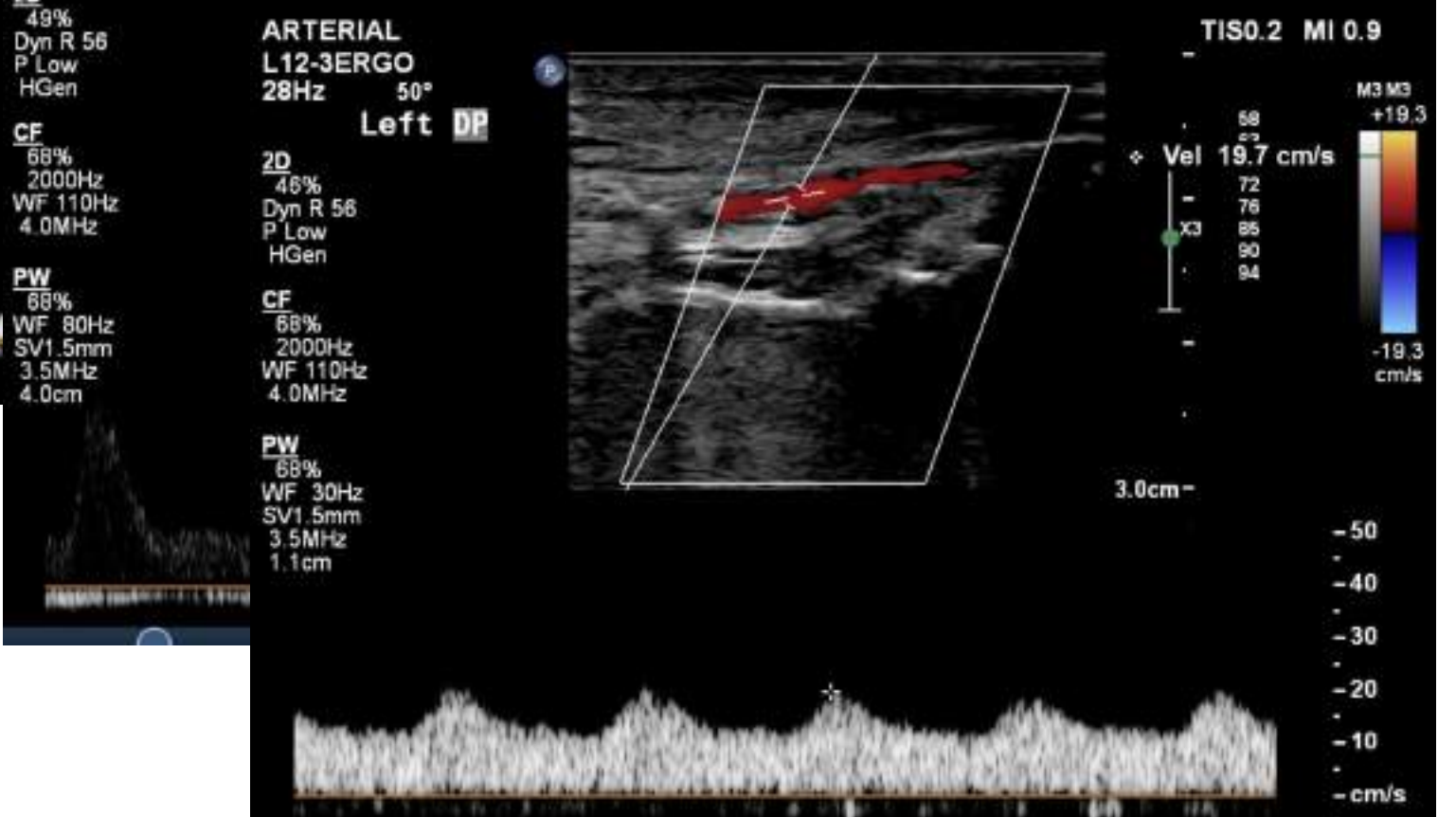
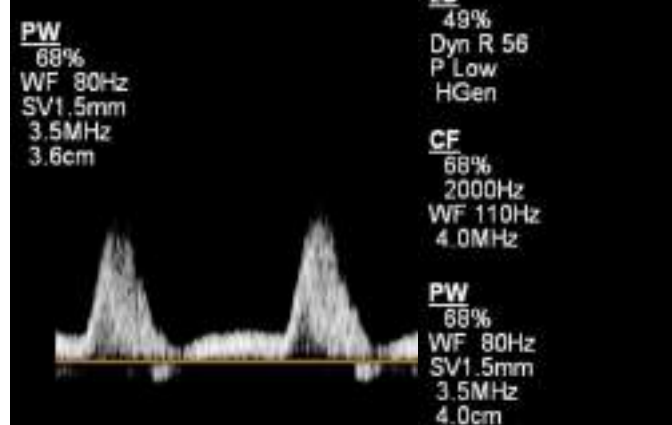
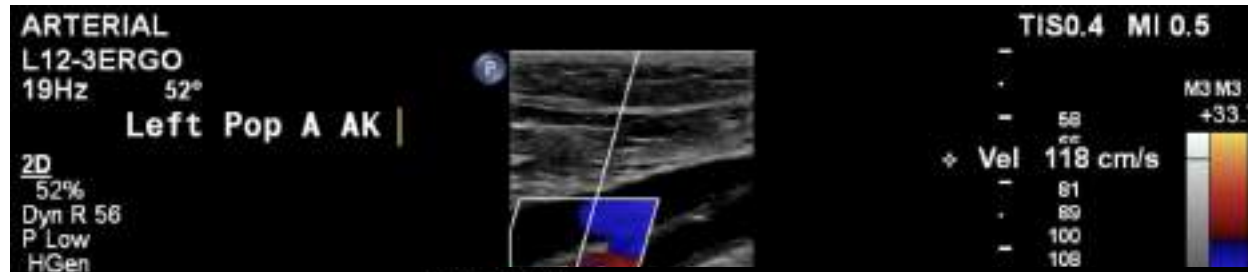
Arterial Duplex



Imaging

Foot X-ray

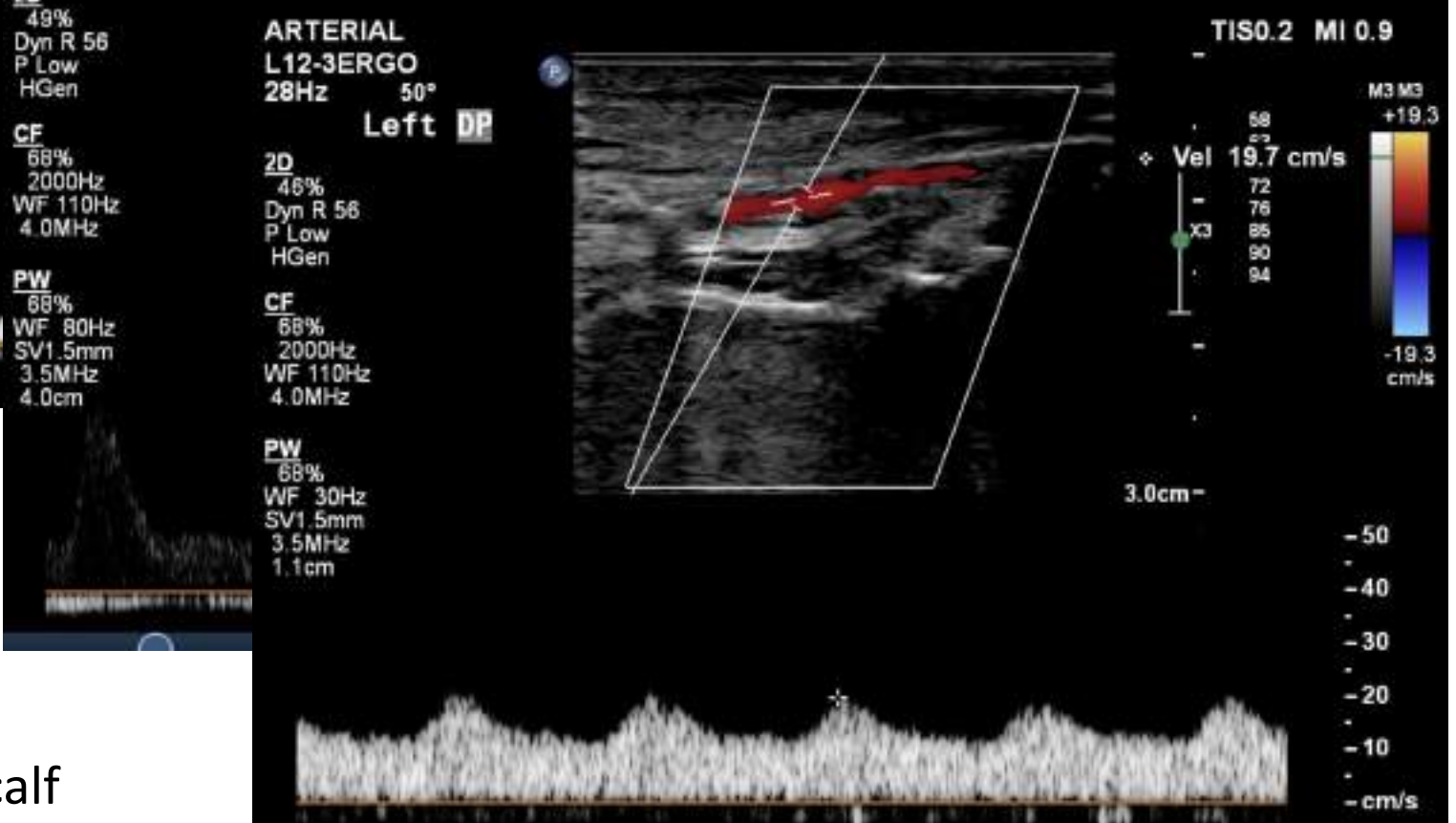
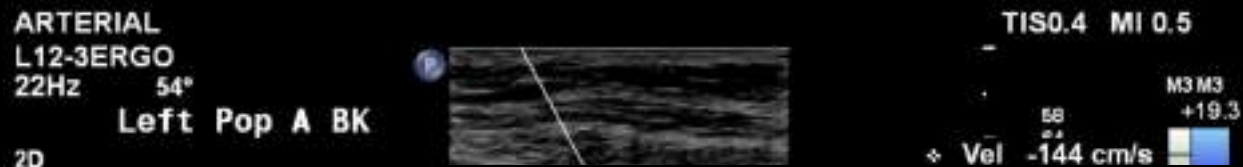
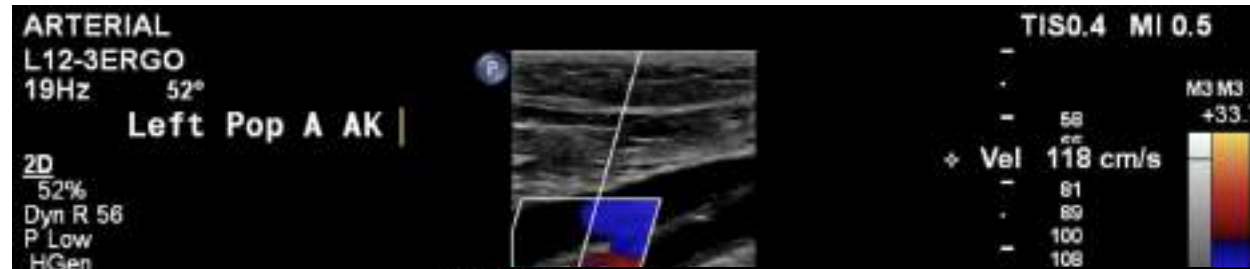
Arterial Duplex



Imaging

Foot X-ray

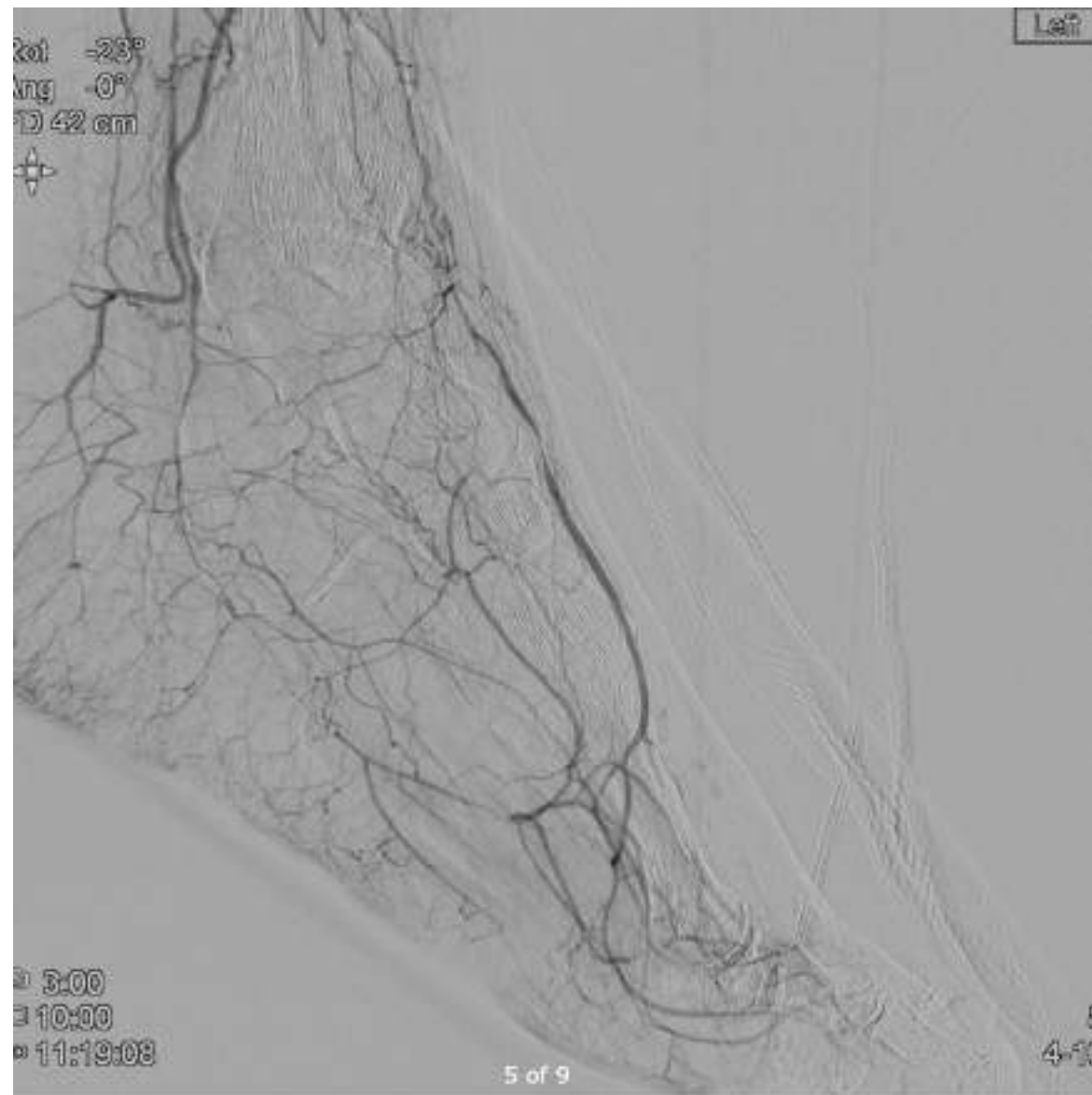
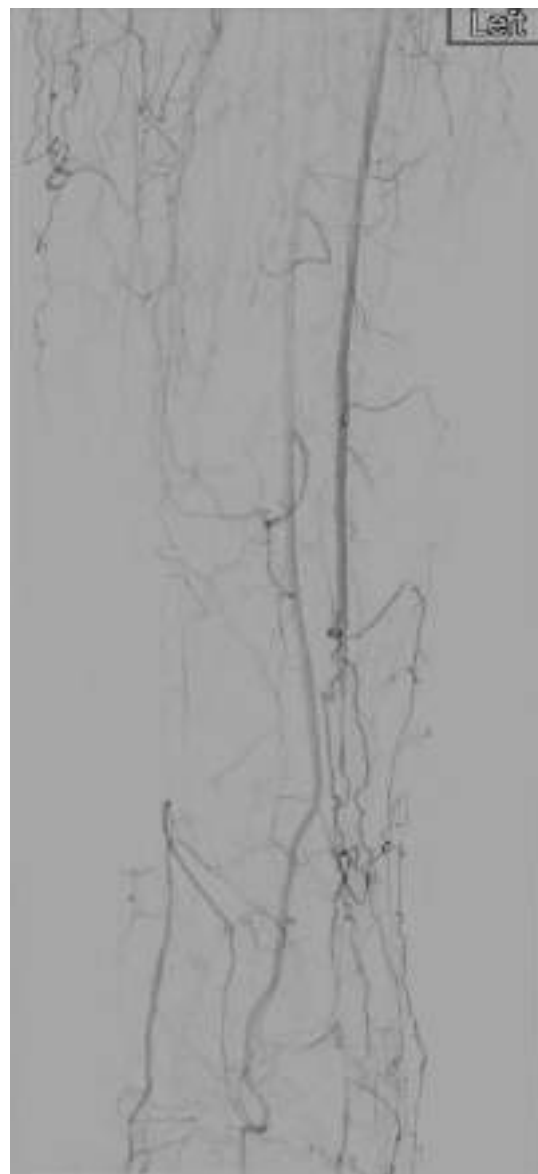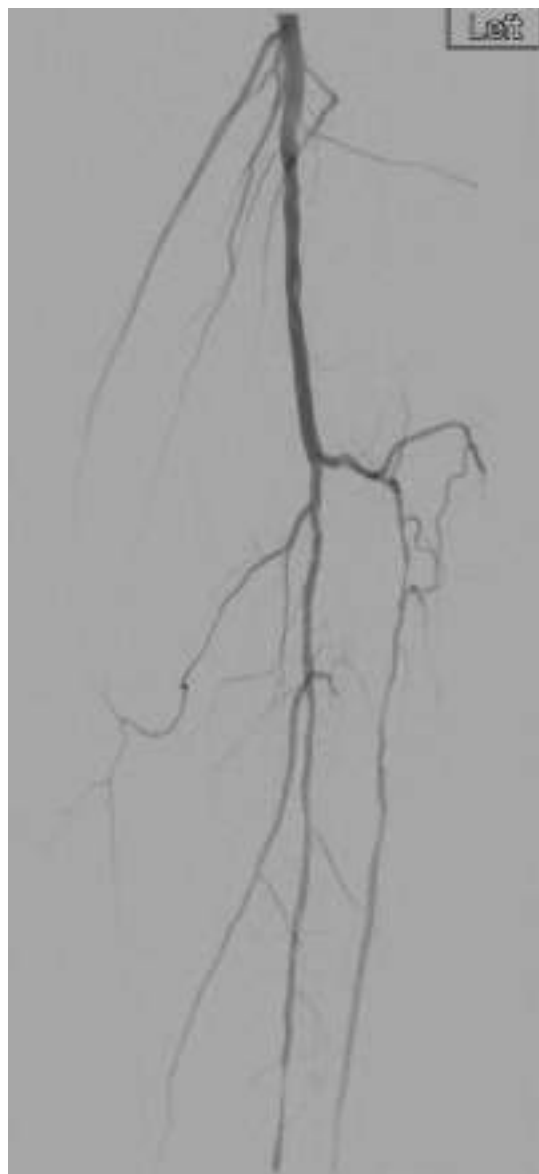
Arterial duplex



Vein map:

GSV 5.4mm in thigh; 3.8mm mid-calf

Imaging

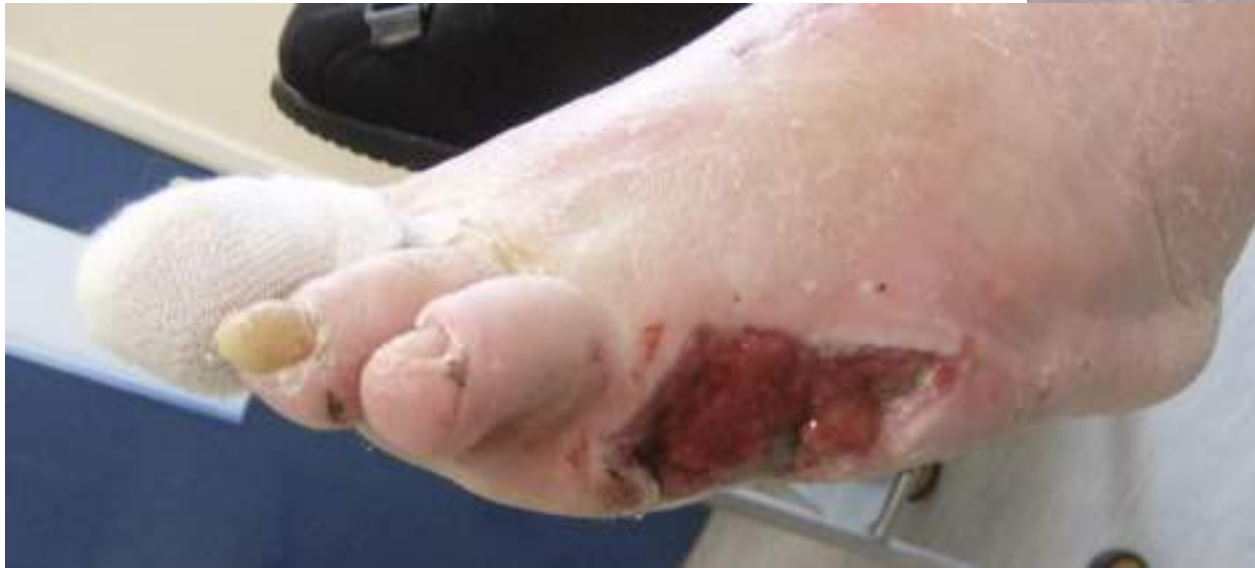
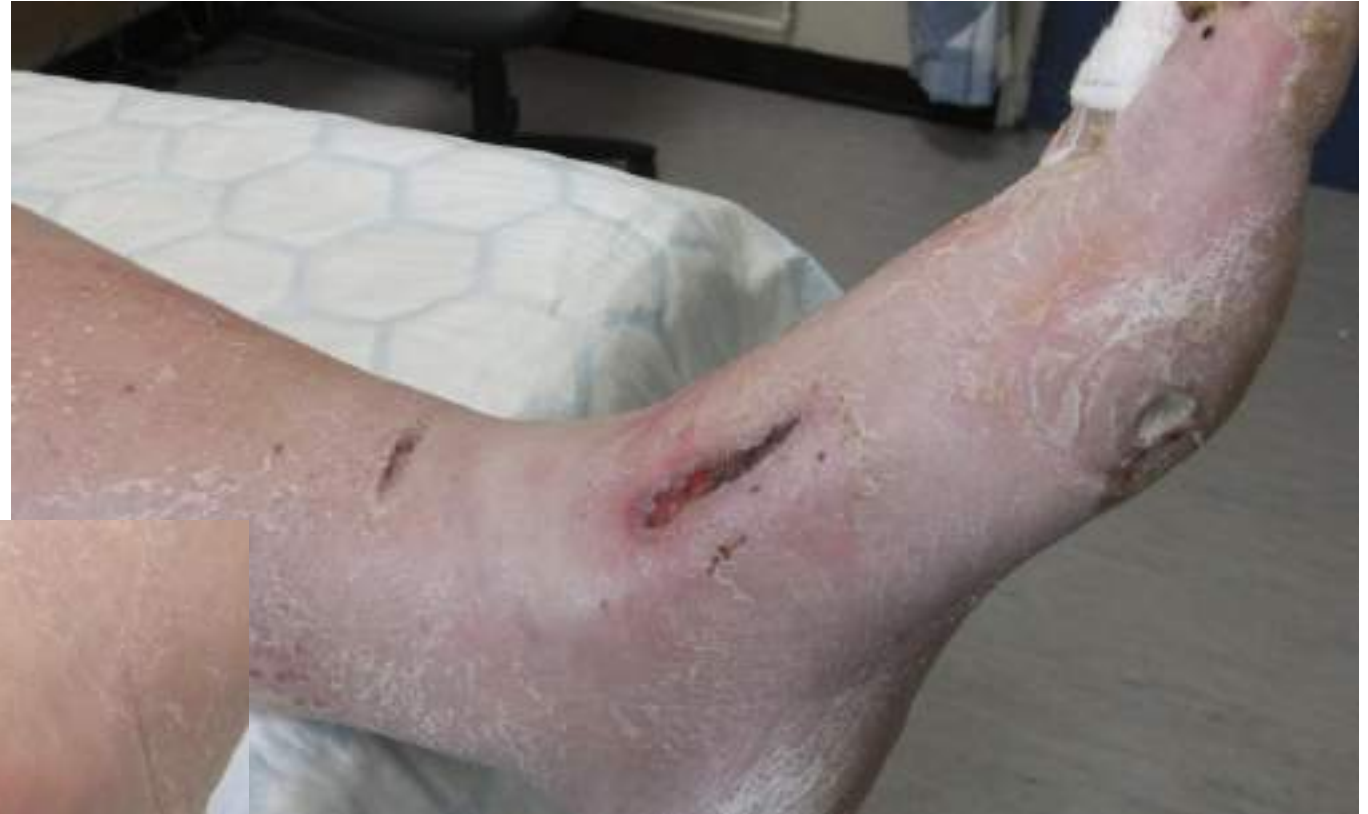
Bypass and 5th ray amputation 13th May 2024

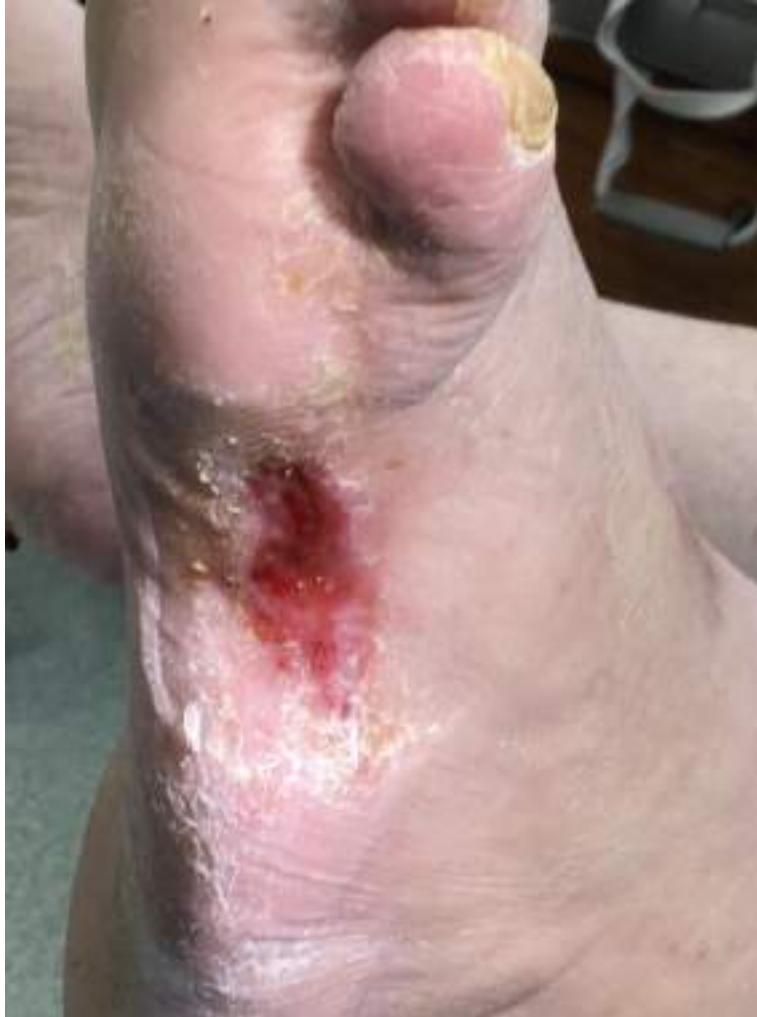- Left BK pop – DP bypass
- Non-reversed ipsilateral GSV
- Esmarch exsanguination and tourniquet for distal anastomosis
- Offset DP incision, tense closure so release incision
- 5th ray amputation
 - clean bone micro and histo +ve for residual osteomyelitis
 - 6 weeks targeted antibiotics (Co-trimoxazole)
 - DAPT as failed to tolerate Rivaroxaban
- Forefoot offloader

Follow-up June 2024

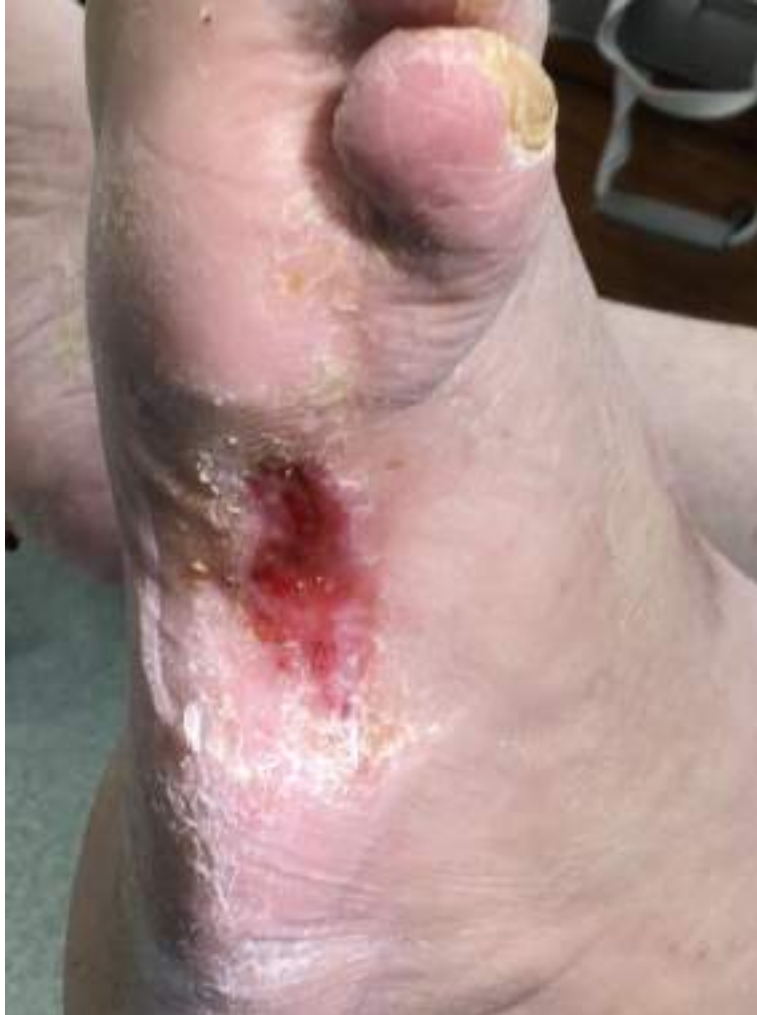- Satisfactory graft surveillance



Follow-up October 2024



Follow-up October 2024



....November 2024

– healed!!

– no photos 🙄